

# BLOOD VESSELS

- ❑ Closed tubular network responsible for transport of blood from the heart to the body and to bring it back.
- ❑ The vessels which carry the blood away from the heart are arteries, and arterioles.
- ❑ The vessels which carry the blood back to heart are veinules and vein.
- ❑ Capillaries are microscopic vessels which join the arteries and veins.

# HISTOLOGY OF BLOOD VESSELS

- ◉ Blood vessels (except capillaries) are made up of three distinct layers called **tunics**. These are:
  - **Tunica interna (internal layer- epithelial lining)**
  - **Tunica media (middle lining- smooth muscles+ elastic connective tissue)**
  - **Tunica externa/adventitia (outer lining -connective tissue covering)**
- The thickness and histologic composition of these three layers differs in arteries, capillaries and veins giving them their unique structure which enables them to perform their unique functions.
- The enclosed space inside the muscular tube is known as **lumen**.

# TUNICA INTERNA

- ◉ The innermost layer
- ◉ It itself is composed of three layers;
  - endothelium,
  - basement membrane and
  - elastic layer
- The endothelium - this layer is in direct contact with lumen.
  - ✓ made up of squamous epithelium.
  - ✓ It surrounds the whole of the CVS.
  - ✓ its smooth surface facilitates the frictionless movement of the blood.
  - ✓ It releases biochemicals which effect the contractile state of the vessels.
  - ✓ Also have role in the platelet aggregation and inflammatory processes.

# TUNICA INTERNA

## ❑ The basement membrane -

- ✓ Present deep to endothelium.
- ✓ Give supportive base to the endothelium
- ✓ Anchors endothelium to connective tissue.
- ✓ Has a framework of collagen fibers which give it flexibility and tensile strength.

## ❑ Elastic layer -

- ✓ Made up of elastic fibers
- ✓ Make boundary between tunica interna and tunica media.

# TUNICA MEDIA

- ◉ Middle layer
- ◉ Composed of smooth muscles and elastic fibers.
- ◉ Display greatest variation in size and composition among different type of blood vessels.
- ◉ The smooth muscles in tunica media regulate the diameter of vessels.
- ◉ It is innervated by sympathetic nervous system which upon stimulation cause smooth muscle to contract and decrease its diameter (vasoconstriction)
- ◉ Play important in blood flow and blood pressure regulation by vasoconstriction and vasodilatation.
- ◉ On its outer side is a layer of elastic fiber which separates it from tunica externa.

# TUNICA EXTERNA

- ◉ Outer covering of the blood vessels.
- ◉ Consists of loose connective tissue.
- ◉ Plays three important roles
  - ◊ Contain capillaries known as vasa vasorum which supplies the large vessel walls with blood
  - ◊ Carry nerve supply to the vessels
  - ◊ Anchors the blood vessels to adjoining tissues.

# ARTERIES

- ◉ Carry blood away from the heart
- ◉ Designed to withstand pressure during systole
- ◉ Classified into three types on the basis of their diameter:
  - ◉ Elastic arteries/ Conducting arteries
  - ◉ Muscular arteries/distributing arteries
  - ◉ Small arteries/ Resistance arteries

## ELASTIC ARTERIES

- ◉ Largest diameter
- ◉ Have high elastic fiber in elastic laminae (internal and external) and tunica media
- ◉ Conduct blood to the muscular arteries
- ◉ Can expand and recoil
- ◉ Function as pressure reservoir
- ◉ Examples : aorta, Pulmonary trunk, subclavian artery

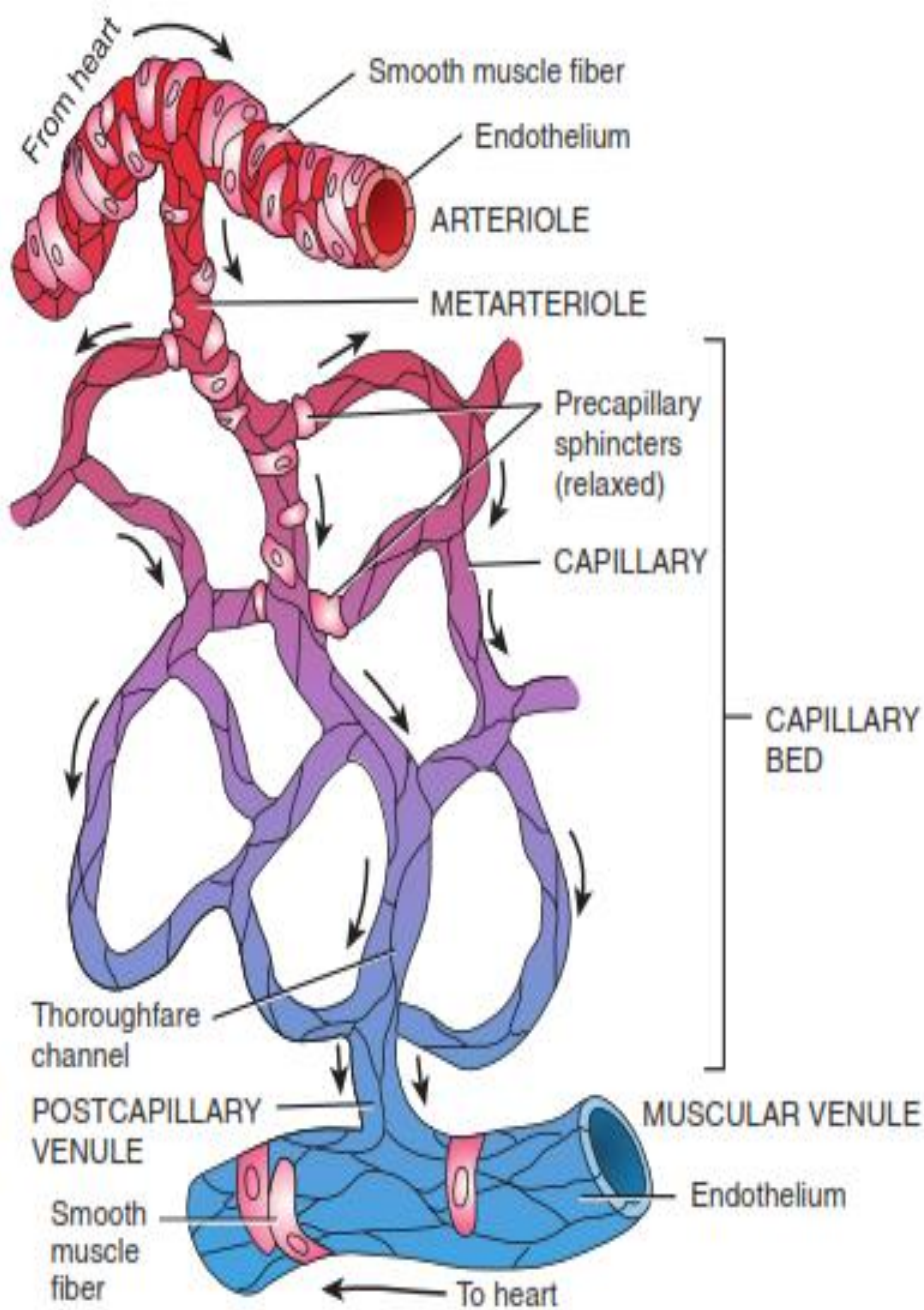


# MUSCULAR ARTERIES

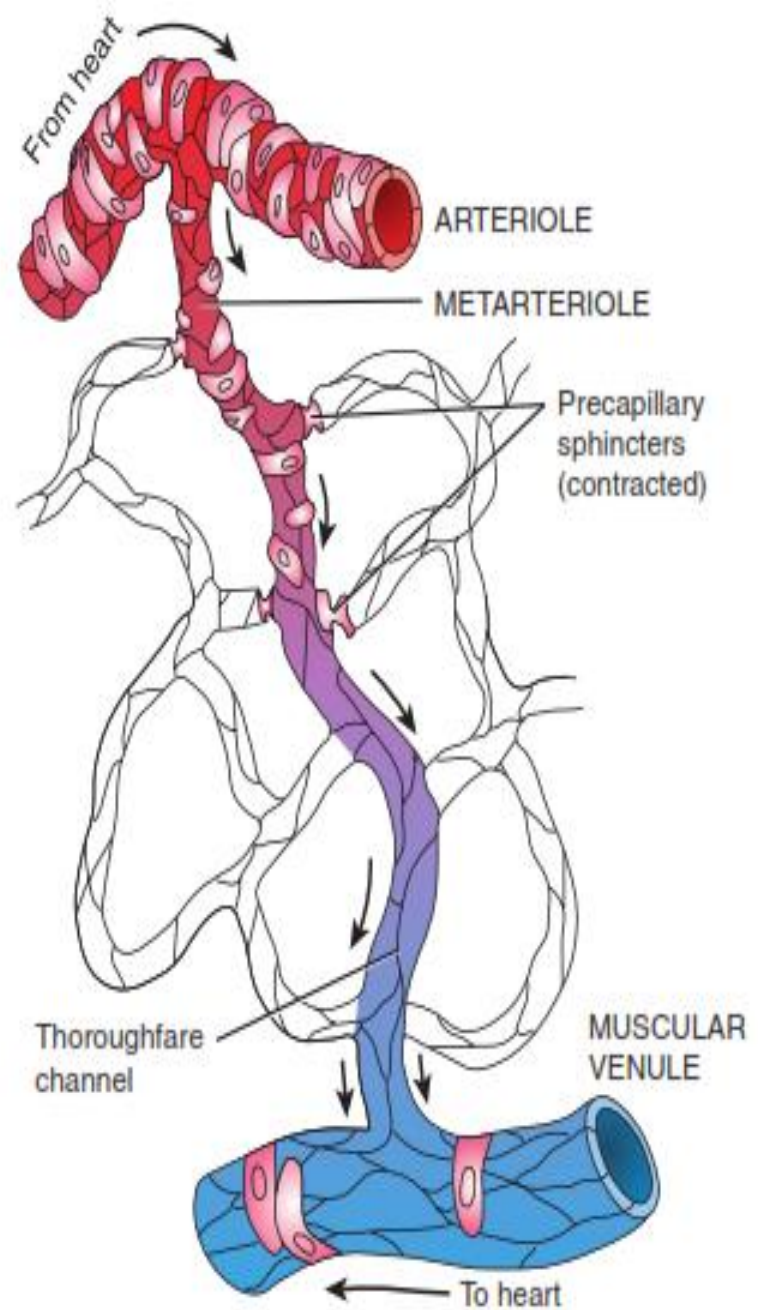
- ◉ Medium sized
- ◉ The tunica media contain more smooth muscle than elastic fibers
- ◉ Have the capacity of vasoconstriction and vasodilatation because of smooth muscles
- ◉ Have thick tunica externa containing collagen fibers and loose connective tissues which allows changes in diameter.
- ◉ Maintain a state of constant contraction called vascular tone which help in flow of blood
- ◉ Examples: Brachial artery, Femoral artery

## SMALL ARTERIES / ARTERIOLES

- ◉ Smallest diameter (15 - 300 micrometer)
- ◉ Has thin tunica interna.
- ◉ The tunica externa has loose connective tissue with sympathetic nerve supply
- ◉ Connects with capillaries.
- ◉ The tapering end or vessel branch of arterioles that join capillaries is called metarterioles
- ◉ The smooth muscles at metarterioles make a ring called precapillary sphincter -regulate flow of blood into capillaries
- ◉ Regulate the blood pressure by altering the resistance to its flow



(a) Sphincters relaxed: blood flowing through capillaries



(b) Sphincters contracted: blood flowing through thoroughfare channel

# CAPILLARIES

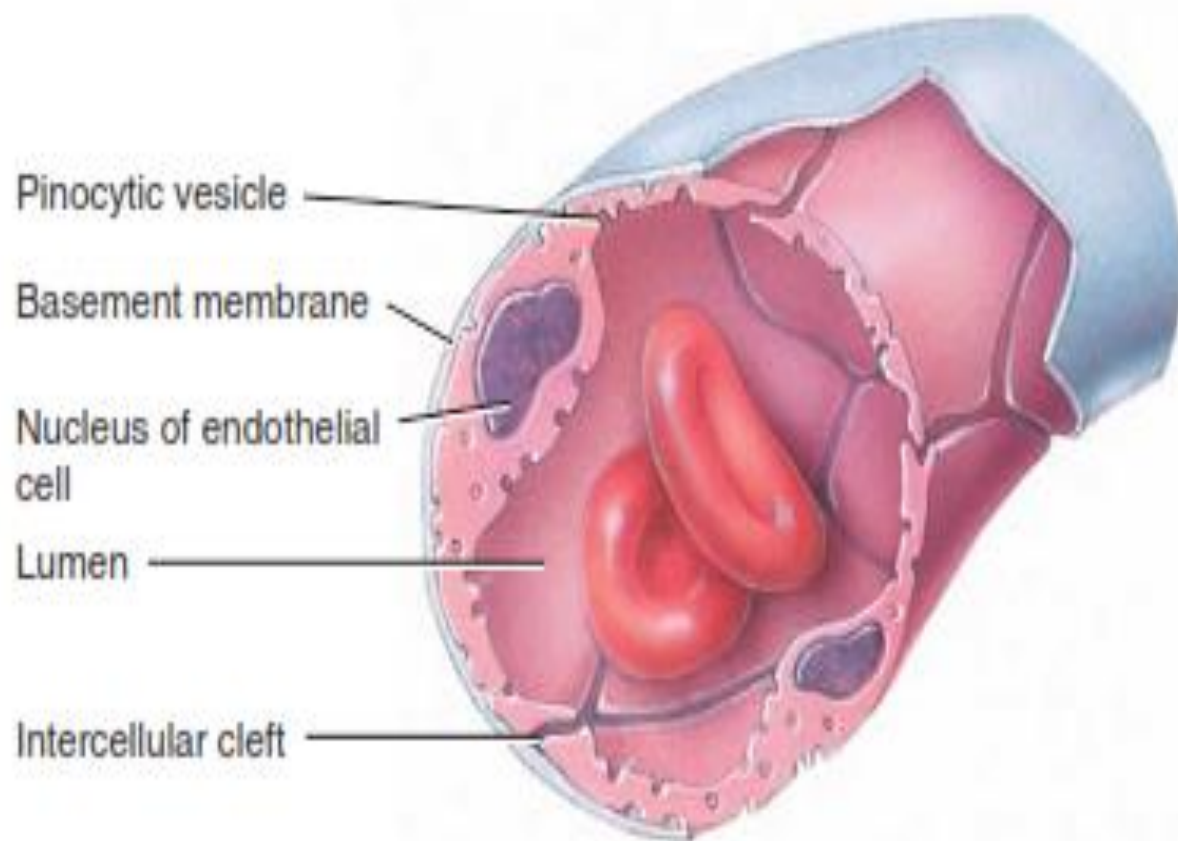
- ◉ Functional unit of cardiovascular system
- ◉ 8- 10 micrometer in size
- ◉ Made up only of endothelial tissue (squamous epithelium) and basement membrane
- ◉ Capillaries exist in clusters called capillary beds
- ◉ Each capillary bed is supplied by a metarteriole.
- ◉ The metarteriole regulate blood supply to the capillaries.
- ◉ The distal end of metarteriole has no smooth muscle and is called thoroughfare channels - provide alternate pathway for the blood flow directly from arteriole to postcapillary venule

# TYPES OF CAPILLARIES

Three types on the basis of structure

## CONTINUOUS CAPILLARIES

- ◉ Most abundant
- ◉ Make continuous tube where cells are held together by tight junctions.
- ◉ Have narrow “intercellular clefts” of about 4 nm in endothelial membrane
- ◉ Allows exchange of small molecules
- ◉ Some exchange takes place by pinocytosis
- ◉ More impermeable in brain (blood brain barrier)
- ◉ Found in brain, muscle tissues, skin



(a) Continuous capillary formed by endothelial cells

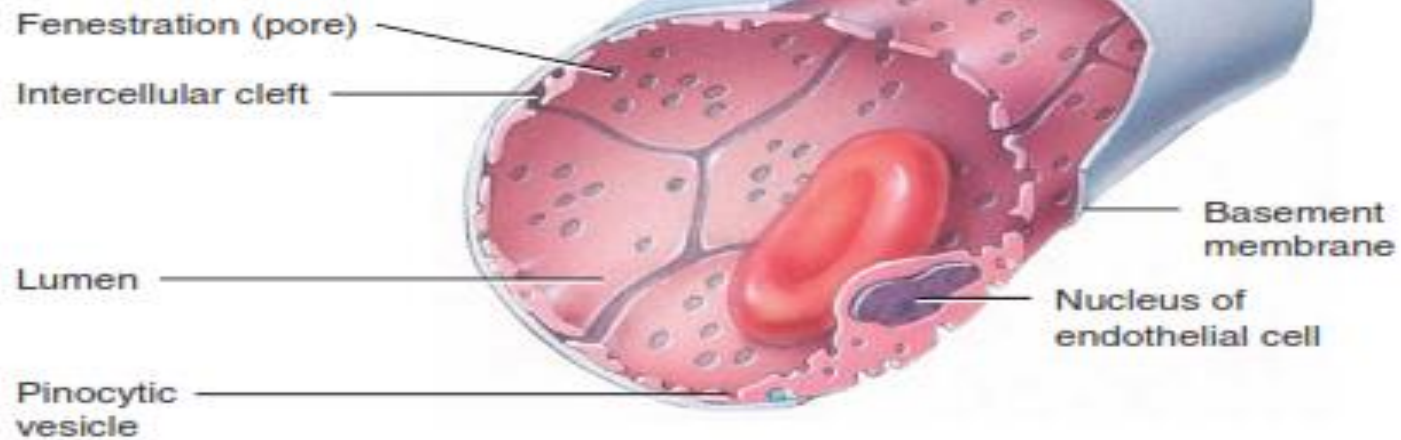


## **FENESTRATED CAPILLARIES**

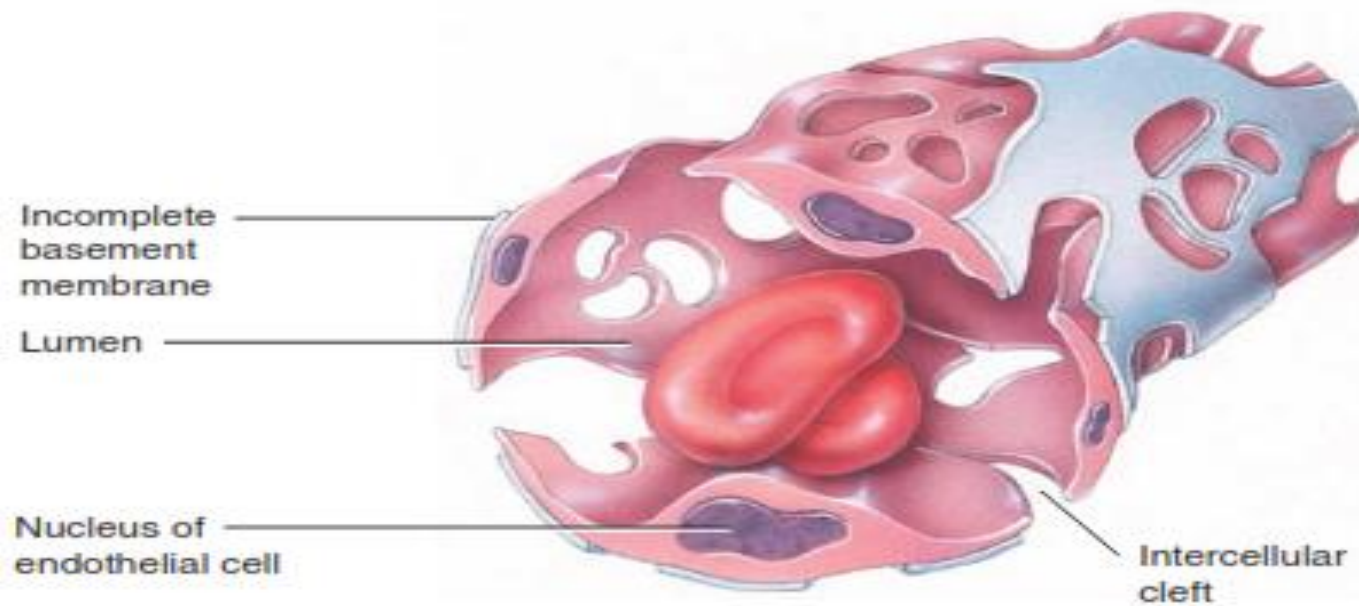
- ◉ In these capillaries the plasma membrane of epithelial cells have small pores of about 70- 100nm called fenestrations
- ◉ Allows exchange of slightly larger molecule but large proteins cannot pass through.
- ◉ Present in those organs which are involved in filtration process or rapid absorption like kidneys, intestine, endocrine glands.

## **DISCONTINUOUS CAPILLARIES**

- ◉ Have large intercellular spaces and discontinuous basement membrane.
- ◉ Allows exchange of proteins and blood cells
- ◉ Line the spleen, liver, bonemarrow



(b) Fenestrated capillary




(c) Sinusoid



# VEINS

- ◉ Collect blood from capillaries and bring it back to heart
- ◉ The blood is delivered from capillaries through microscopic vessels called **post capillary veinules**- porous, lack smooth muscles.
- ◉ Join to form muscular veinules- acquire smooth muscles, lose porosity.
- ◉ Veinules serve as blood reservoirs because of their distensibility.
- ◉ Veinules join to form veins - have all three layers , avg diameter ranges from 5 mm to 3 cm.
- ◉ Have thin tunica interna and media, thick tunica externa
- ◉ Lack elastic laminae.
- ◉ To facilitate the return of blood from veins to heart under low pressure veins have valves called venous valves made up from tunica interna along with collagen fibers.
- ◉ Veins generally pass between skeletal muscles whose squeezing effects facilitate venous return. This is known as skeletal muscle pump

Transverse plane



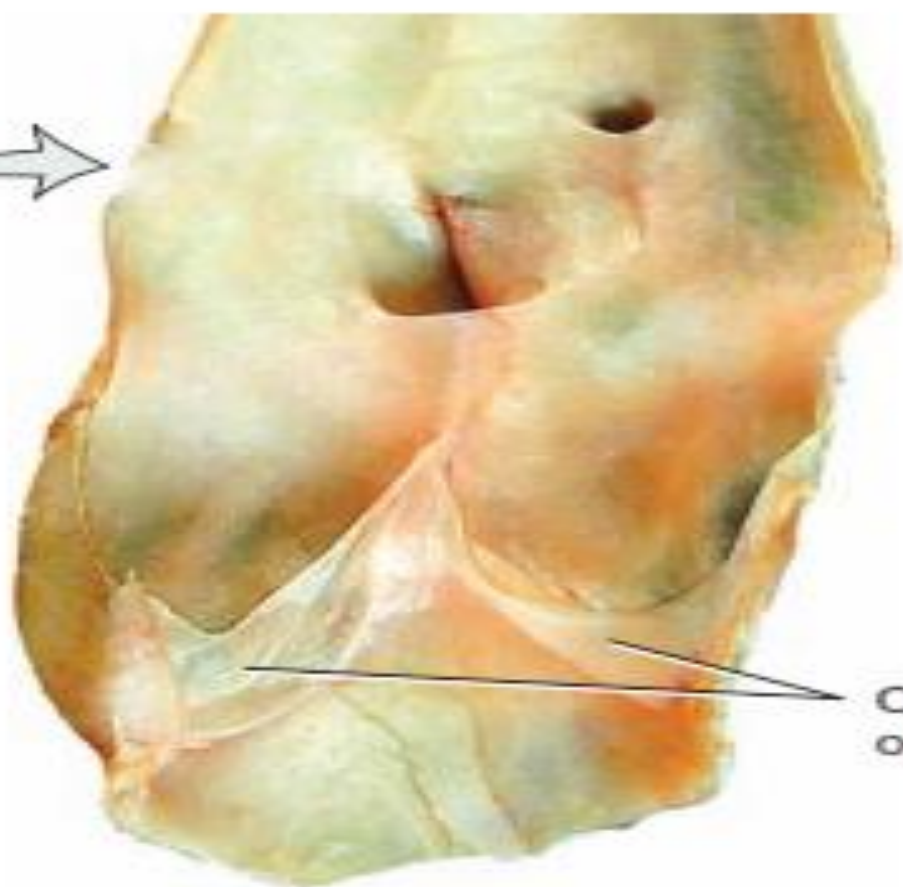
Vein

Frontal plane



Cusps of valve

Transverse section, superior view



Cusps of valve

Longitudinally cut

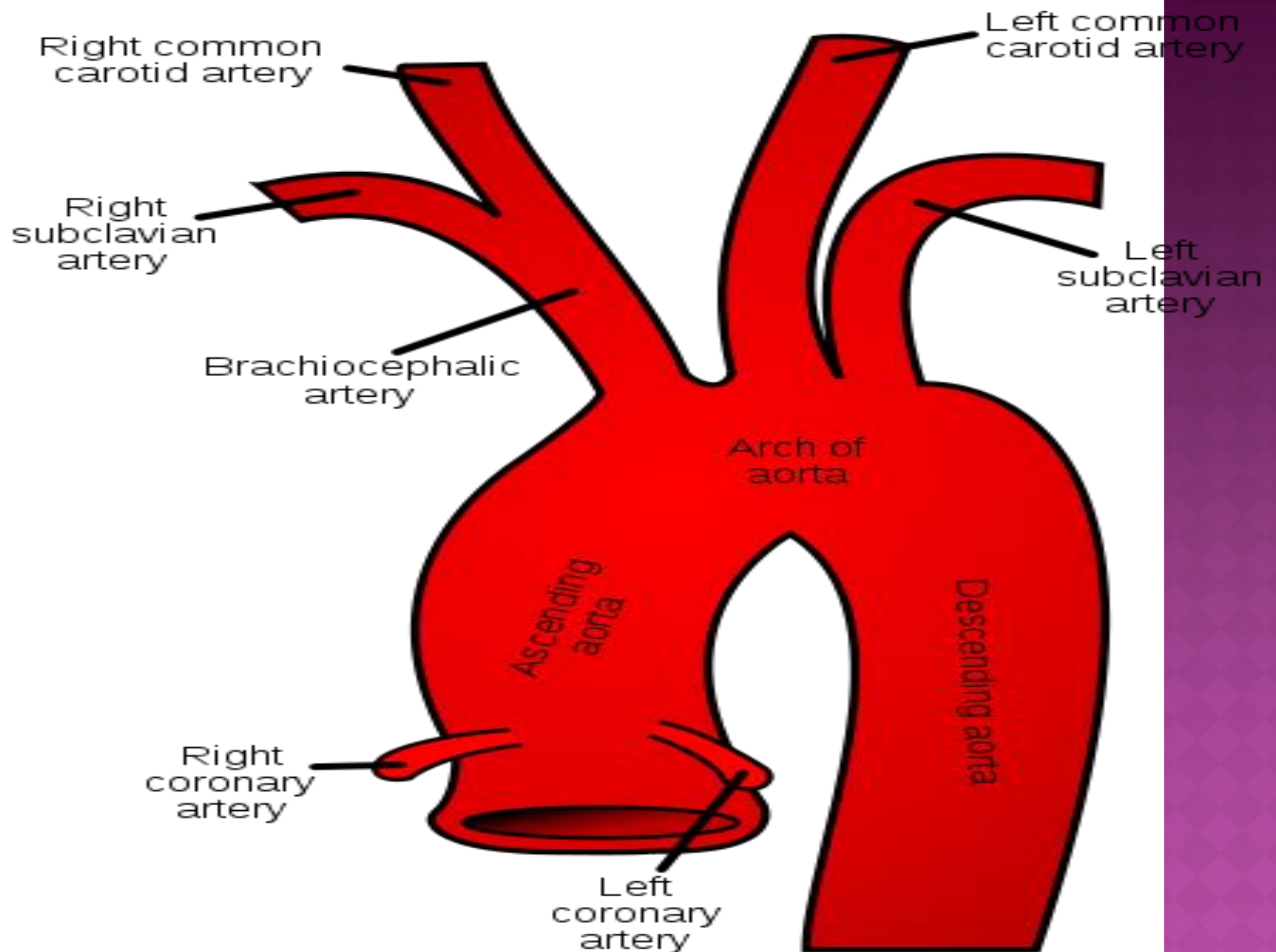
Photographs of valve in vein

- ◉ **Vascular sinus** - is a vein with a thin endothelial wall that has no smooth muscle to alter its diameter. In a vascular sinus, the surrounding dense connective tissue replaces the tunica media
- ◉ **Portal veins** - blood passes from one capillary network into another through a vein called a portal vein. Such a circulation of blood is called a portal system. E.g. hepatic portal vein
- ◉ **Anastomosis** - The union of the branches of two or more vessels supplying the same body region is called an anastomosis. Both arterial and venous anastomosis possible.
- ◉ **Varicose veins** - Varicose veins are swollen and twisted veins that have filled with an abnormal collection of blood resulting from incompetent valves
- ◉ **Hemorrhoids** - Hemorrhoids are painful, swollen veins in the lower portion of the rectum or anus.
- ◉ **Esophageal varices** - Esophageal varices are abnormal, enlarged veins in the lower part of the esophagus

# ARTERIAL SYSTEM

## SYSTEMIC CIRCULATION

- ◉ All the systemic arteries arise from **aorta**
- ◉ The aorta is the largest artery of the body, with a diameter of 2-3 cm
- ◉ It emerges from the left ventricle posterior to pulmonary trunk
- ◉ On the basis of anatomic location it can be divided into four segments:
  - I. The ascending aorta
  - II. The arch of aorta
  - III. The thoracic aorta
  - IV. Abdominal aorta



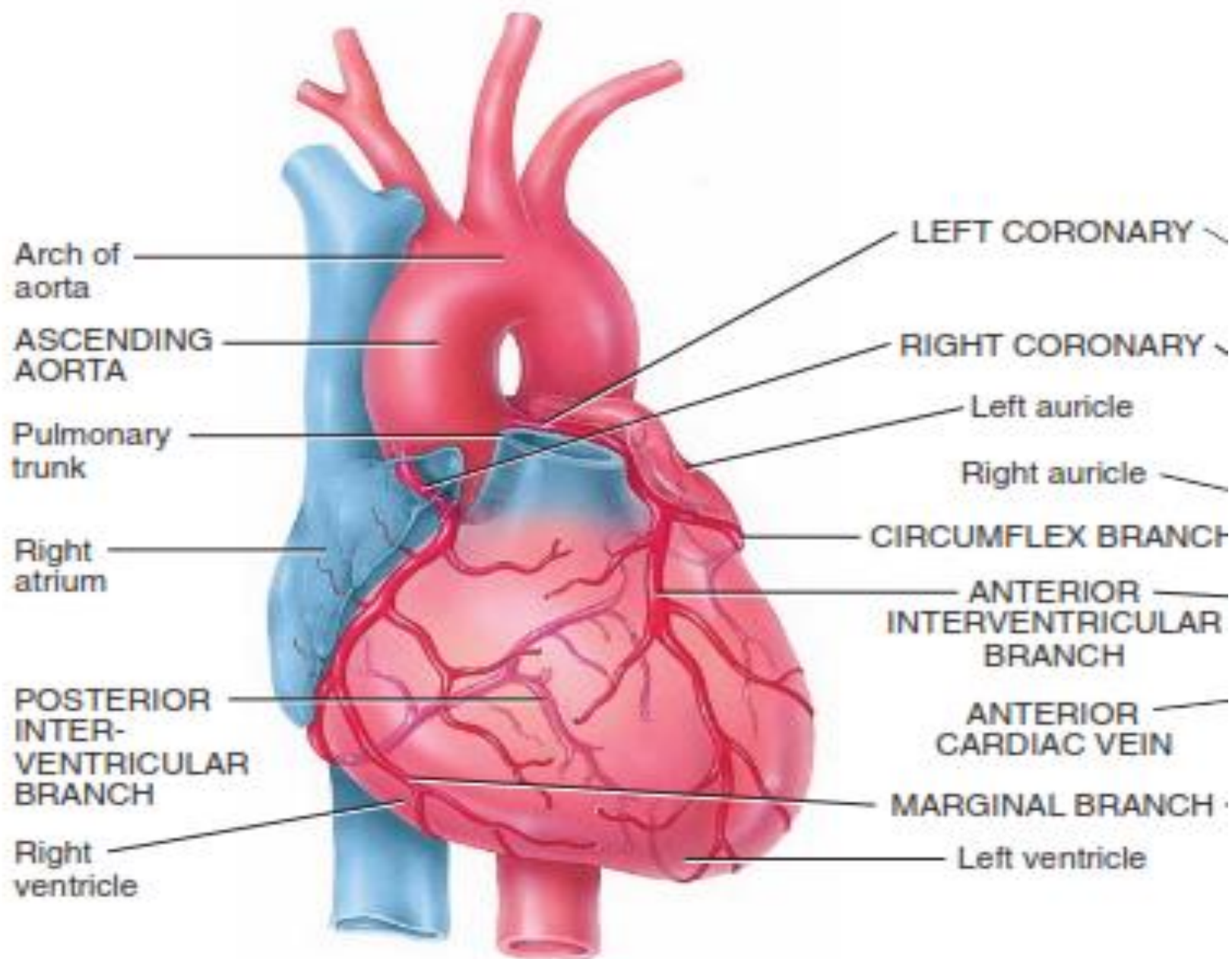
# ASCENDING AORTA

- Portion of the aorta that emerges from the left ventricle posterior to the pulmonary trunk is the ascending aorta
- Starts at the position of right auricle, moves superior and anterior towards right and ends at the level of sternal angle where it becomes arch of aorta.
- The ascending aorta is about 5 cm in length and begins at the aortic valve
- It is covered by pericardium.
- Three bulges of the aorta are called sinuses of aorta
- The ascending aorta gives off two coronary arteries, one from anterior aortic sinus called right coronary artery and other from posterior aortic sinus called left coronary artery.
- The coronary arteries divides to form coronary circulation.



Diagram

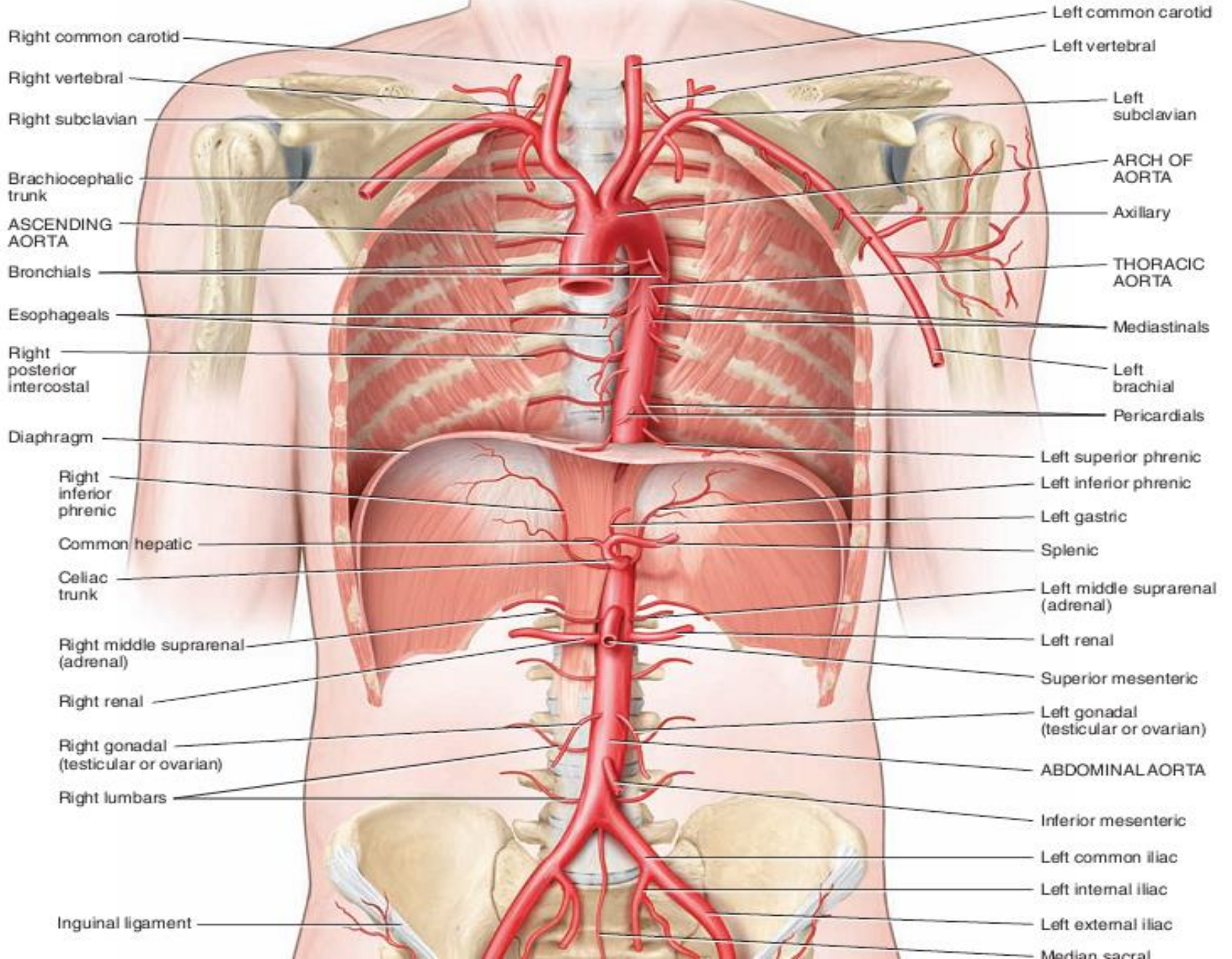
Diagram



# ARCH OF AORTA

- ◉ It is continuation of aorta.
- ◉ Emerges from pericardium posterior to the sternum
- ◉ Starts at the level of sternal angel, moves superior and posterior and then turn inferior (making an arch), ending at the intervertebral disc between 4<sup>th</sup> and 5<sup>th</sup> vertebrae where it become thoracic aorta.
- ◉ Three main arteries emerges from the arch of aorta
  - I. The brachiocephalic artery
  - II. The left common carotid artery
  - III. The left subclavian artery





Right common carotid

Right subclavian

Trachea

Brachiocephalic

Right internal thoracic  
(mammary)

Arch of aorta

Left subclavian

Clavicle (cut)

First rib (cut)

Left axillary

Left common carotid


Vagus nerve (recurrent  
laryngeal branch)

Phrenic nerve

Left lung

Pulmonary trunk

Heart





# THE BRACHIOCEPHALIC ARTERY

- It is the first and largest branch from the aorta
- Arise from the superior aspect of arch of aorta moves superiorly to the right and at the sternoclavicular joint divides into two branches:

- I. **The right subclavian artery**
- II. **The right common carotid artery**

## III. **THE RIGHT SUBCLAVIAN ARTERY:**

- Extends from brachiocephalic artery to inferior border of first rib
- Give off following branches at the base of the neck:
  - **Internal thoracic artery:** Arises from first part of subclavian artery, descends posterior to costal cartilages of superior six ribs terminates at sixth intercostal space sending branches into intercostal spaces
  - **Vertebral artery:** a major branch to the brain
  - **Thyrocervical artery:** a short trunk serving thyroid gland, trachea, shoulder and larynx
  - **Costocervical artery:** serve the upper intercostal muscles, posterior neck muscles, and the spinal cord and its meninges.

## AXILLARY ARTERY

- After giving off these branches in thoracic cavity, the right subclavian artery enters the axillary region at the inferior border of first rib. Here it is known as **axillary artery**
- It gives off numerous branches at axilla supplying blood to the upper thorax and shoulder region
- It ends at the distal end of teres major muscle

## BRACHIAL ARTERY

- It is the continuation of axillary artery to arm  
(Subclavian, axillary and brachial artery is the same artery with different name at different locations)
- Superficial and palpable at the medial side of the arm
- As it descends through the elbow joint it curves laterally passing through cubital fossa where it is easily palpable
- It supplies blood to muscles of arm, humerus and elbow joint
- Gives off deep brachial artery (supplies triceps brachii) and anterior and posterior humeral circumflex arteries (forms anastomotic network around humerus)
- Terminates by dividing into **radial and ulnar arteries** proximal to cubital fossa

## Arteries of the fore arm:

- Just proximal to the cubital fossa,( a triangular depression that lies in front of the elbow ) the brachial artery branches into the radial and ulnar arteries, which supply blood to the forearm, hand and digits.

## The radial artery

- R.A courses down the lateral, or radial, side of the arm, where it sends numerous small branches to the muscles of the forearm.
- Branches of radial arteries:
- The radial recurrent artery*  
serves the region of the elbow and is the first and largest branch of the radial artery.
- The radial artery divides into *deep radial artery* and *superficial radial artery* at the wrist

# Ulnar artery:

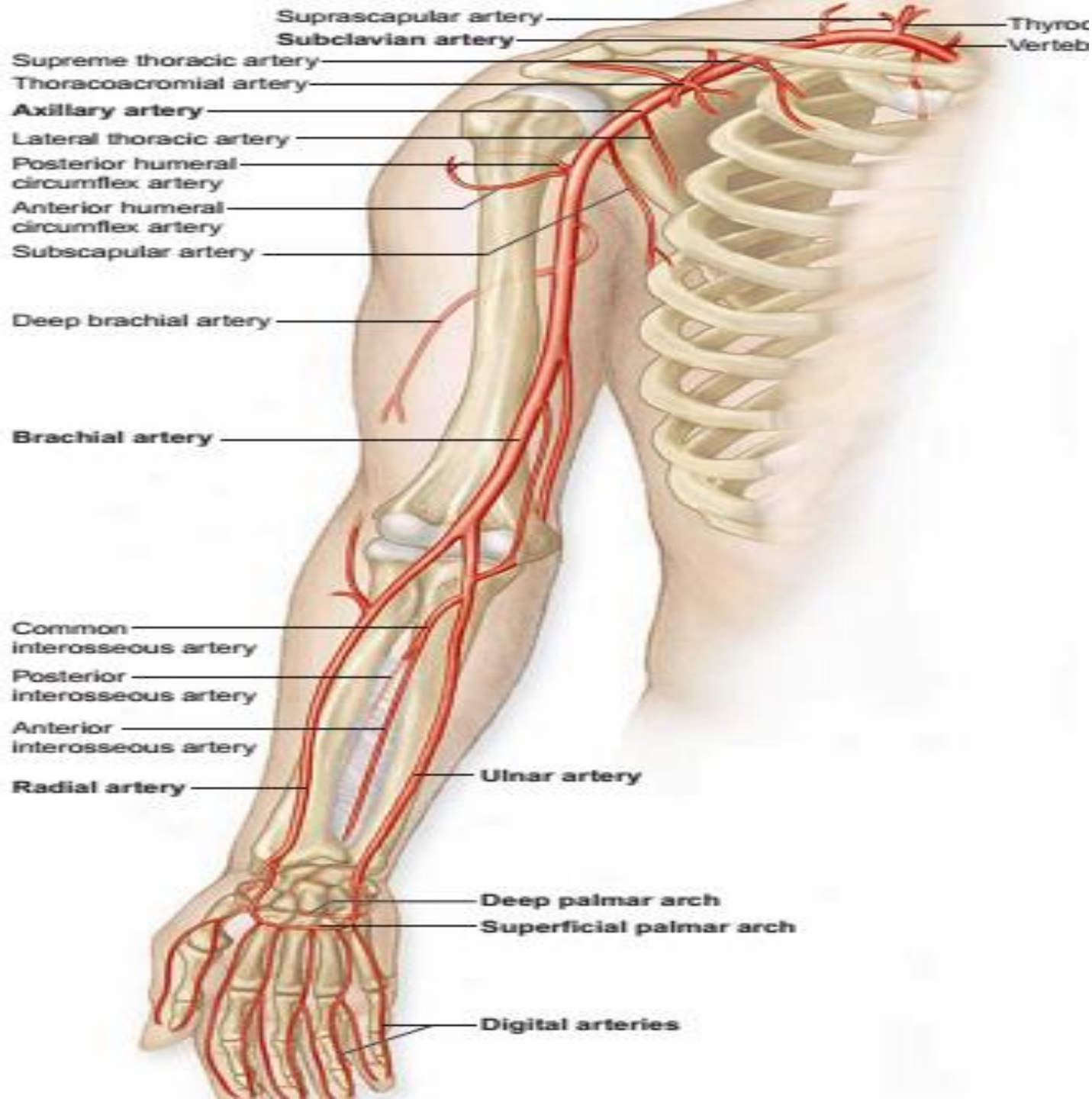
- Large among the 2 from brachial artery
- The ulnar artery extends down the medial, or ulnar, side of the forearm and gives off many small branches to the muscles on that side.
- Branches of Ulnar Arteries:
- 1:Ulnar recurrent artery, which arises from the proximal portion near the elbow.
- 2: Common interosseous artery which divides into anterior and posterior interosseous arteries.
- 3: At wrist it branches into superficial and deep branches that enter hand
- The branches of radial and ulnar arteries anastomose giving rise to **palmar arches**

## **SUPERFICIAL PALMER ARCH**

- ◉ Formed mainly by superficial palmar branch of ulnar artery with contribution from superficial branch of radial artery
- ◉ Present superficially on palm
- ◉ Gives off digital arteries to the fingers

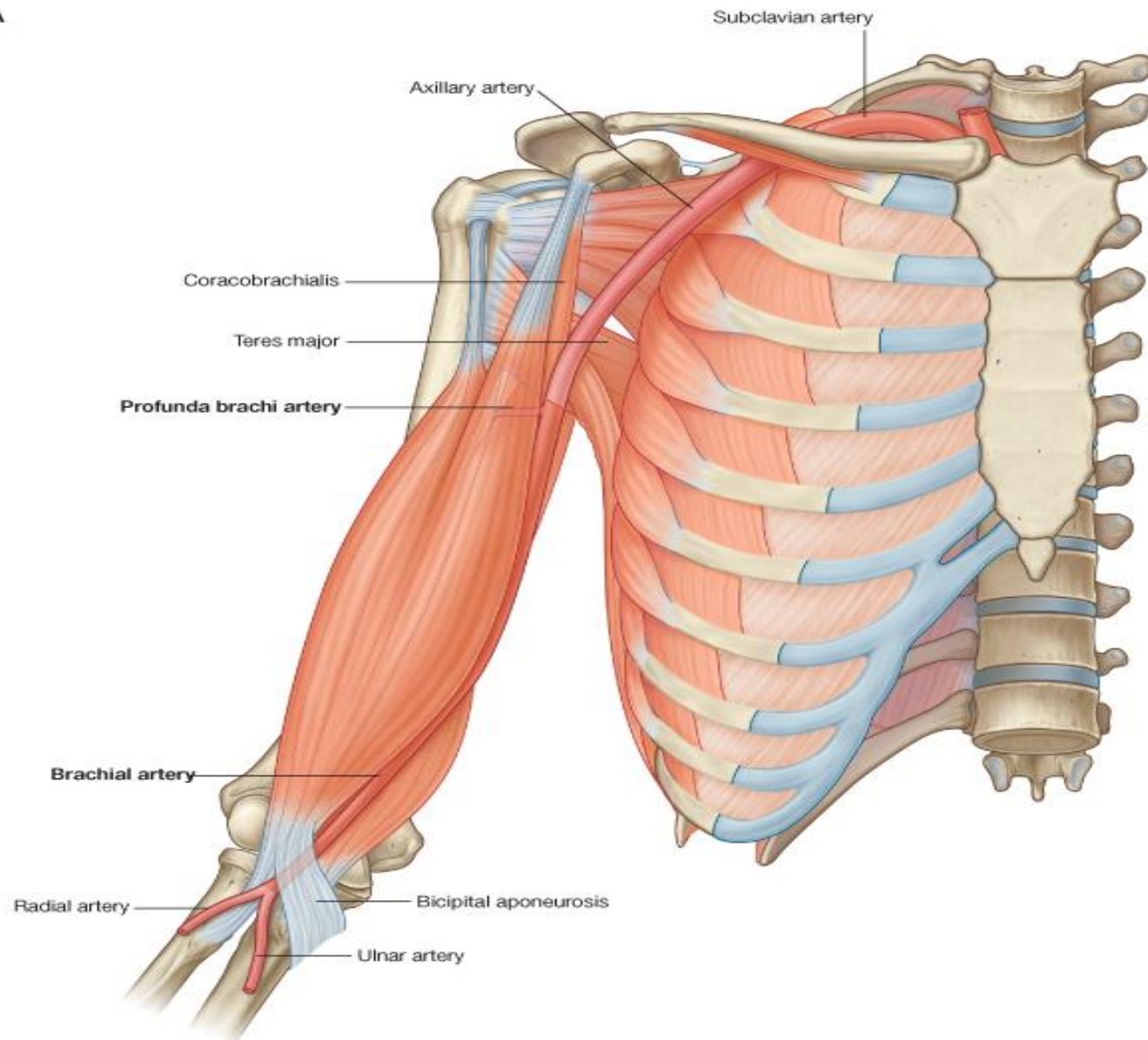
## **DEEP PALMER ARCH**

- ◉ Arises mainly from deep palmar branch of radial artery with contribution from deep branch from ulnar artery
- ◉ Present deep in palm
- ◉ Give rise to metacarpal arteries

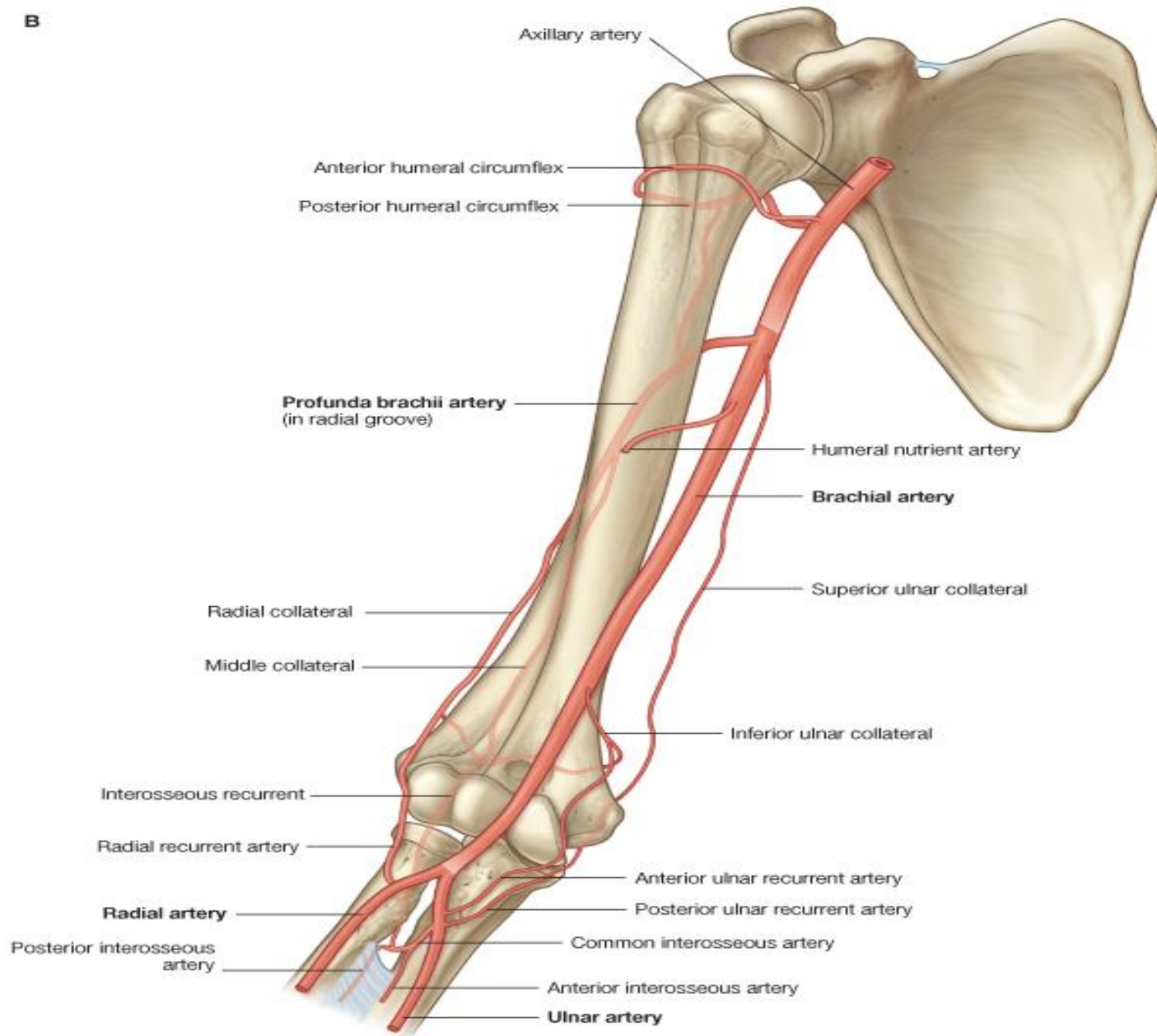


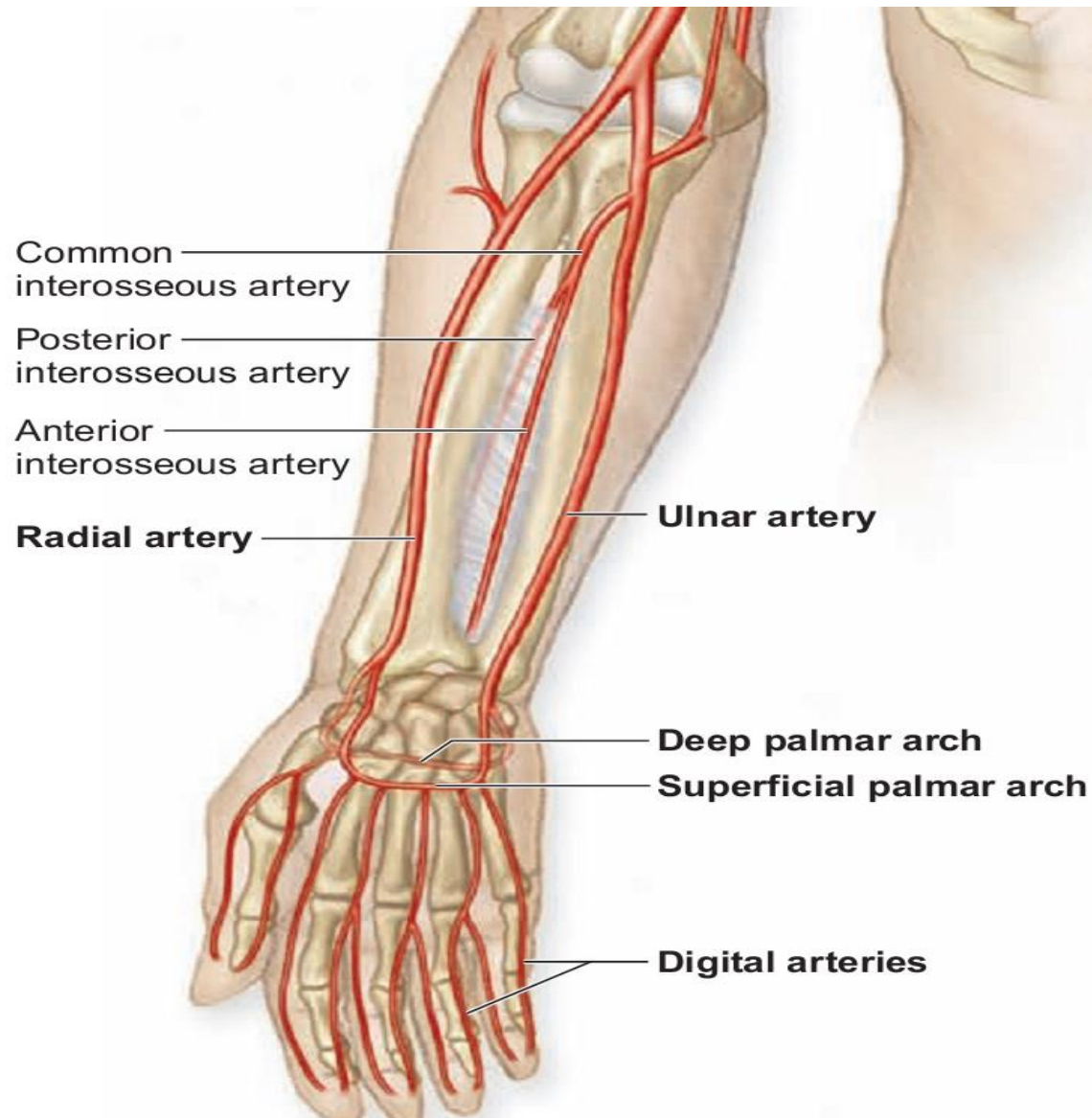


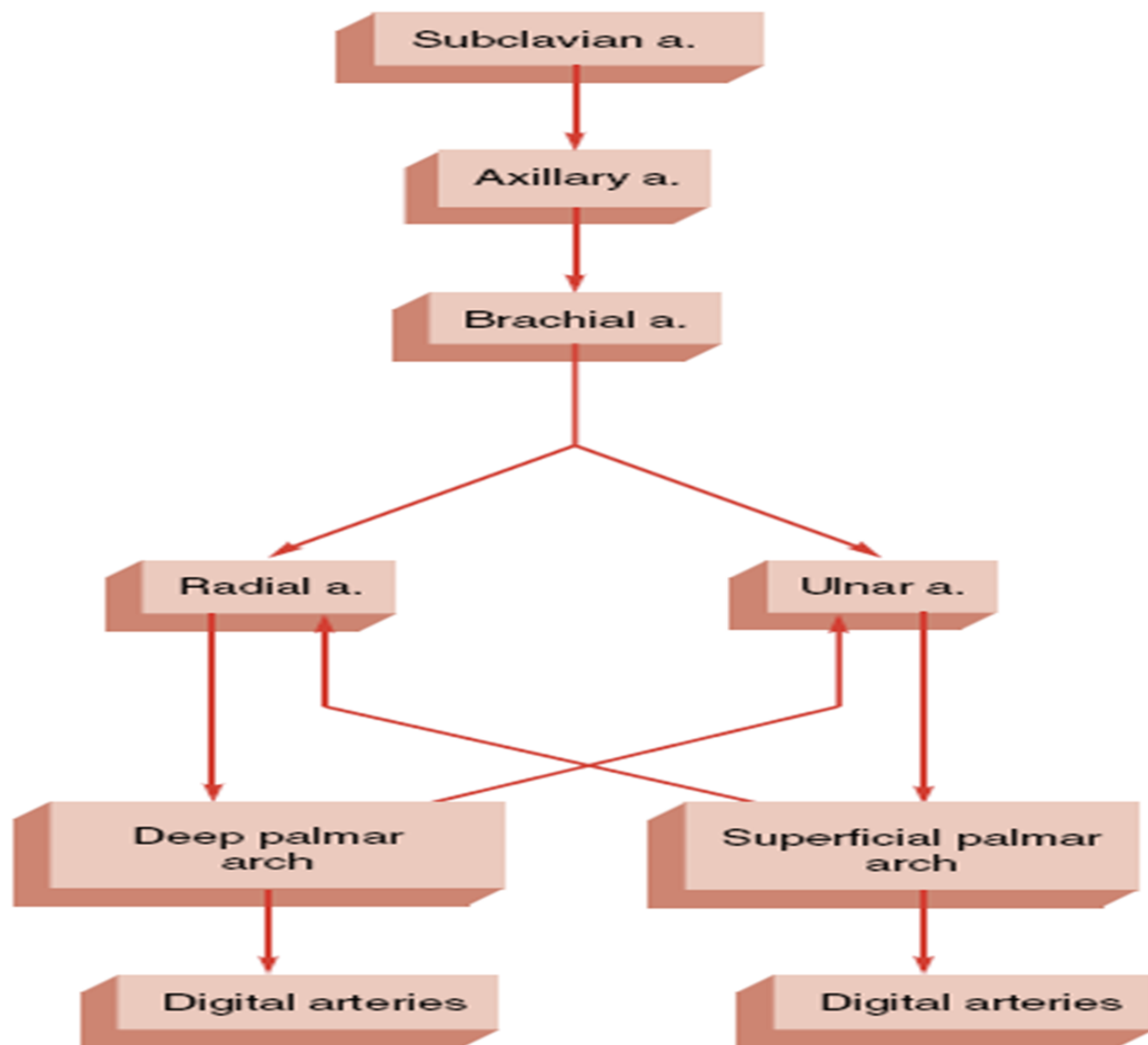
**A**



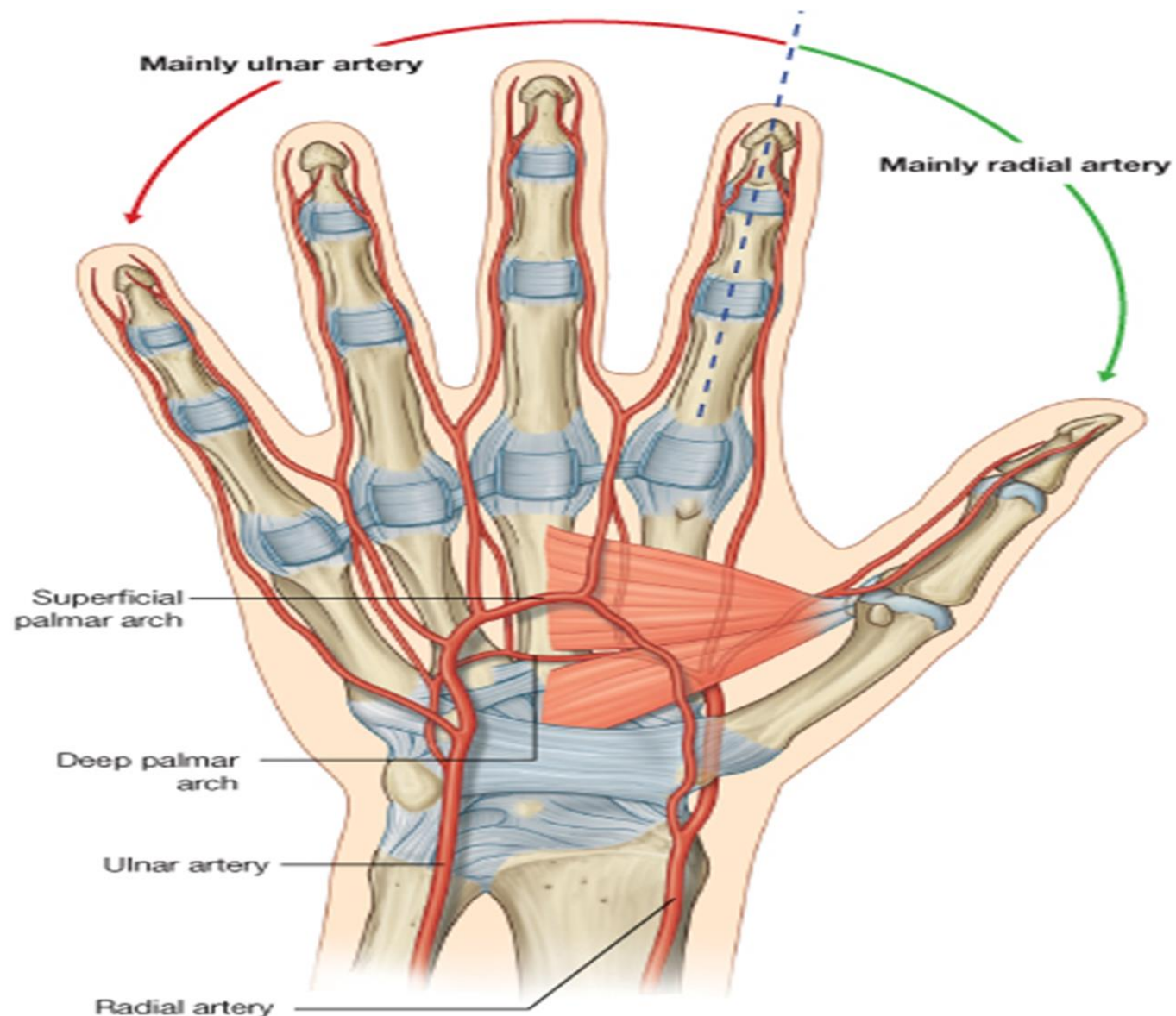
**B**











# COMMON CAROTID ARTERIES

- ◉ The common carotid arteries course upward in the neck along the lateral sides of the trachea.
- ◉ Right common carotid artery emerge from bifurcation of the brachiocephalic trunk while the left common carotid artery emerge directly from the arch of aorta.
- ◉ Each common carotid artery branches into the internal and external carotid arteries slightly below the angle of the mandible.
- ◉ At the base of the internal carotid artery is a slight dilation called the carotid sinus. The carotid sinus contains baroreceptors, which monitor blood pressure.
- ◉ Surrounding the carotid sinus are the carotid bodies, small neurovascular organs that contain chemoreceptors, which respond to chemical changes in the blood.
- ◉ The internal carotid artery ascends in the neck until it reaches the base of the skull, where it enters the carotid canal of the temporal bone.

- ◉ The internal carotid artery gives off branches during its course. The important among which are:
  - ▣ Ophthalmic artery: supply eye and associated structures
  - ▣ Cerebral arteries ( anterior and middle): supplies the cerebrum
- The paired internal carotid arteries along with paired vertebral arteries (of subclavian arteries) make the four arteries that supply brain.
- At the inferior surface of the brain around the pituitary gland the branches of these vessels anastomose making a the **cerebral arterial circle or the circle of willis**

# THE CIRCLE OF WILLIS

The circle of willis is formed by two vertebral arteries and two carotid arteries:

## The vertebral arteries

- ✓ arise from the subclavian artery at the base of neck pass superiorly through the cervical vertebrae and enter the skull through the foramen magnum
- ✓ In the cranium (at the level of pons) they unite to form basilar artery
- ✓ The basilar artery ascends along the inferior surface of the brain stem and terminates by forming two posterior cerebral arteries that supply the posterior portion of the cerebrum
- ✓ Posterior cerebral arteries give rise to the posterior communicating arteries

## The internal carotid artery

- ✓ On the anterior side the internal carotid arteries give off cerebral arteries which anastomose with each other through anterior communicating artery
- ✓ On the posterior side the internal carotid arteries anastomose with the posterior communicating arteries

The anastomoses of vertebral arteries making basilar artery, the anastomoses at anterior communicating artery and anastomoses of internal carotid arteries with posterior communicating arteries collectively make the circle of willis



Cerebral arteries:

Anterior

Middle

Basilar a.

Vertebral a.

Spinal aa.

Anterior  
cerebral a.

Middle  
cerebral a.

Posterior  
communicating a.

Posterior  
cerebral a.

Anterior  
communicating a.

Internal  
carotid a.

Pituitary  
gland

Basilar a.

(b)

Cerebellar arteries:

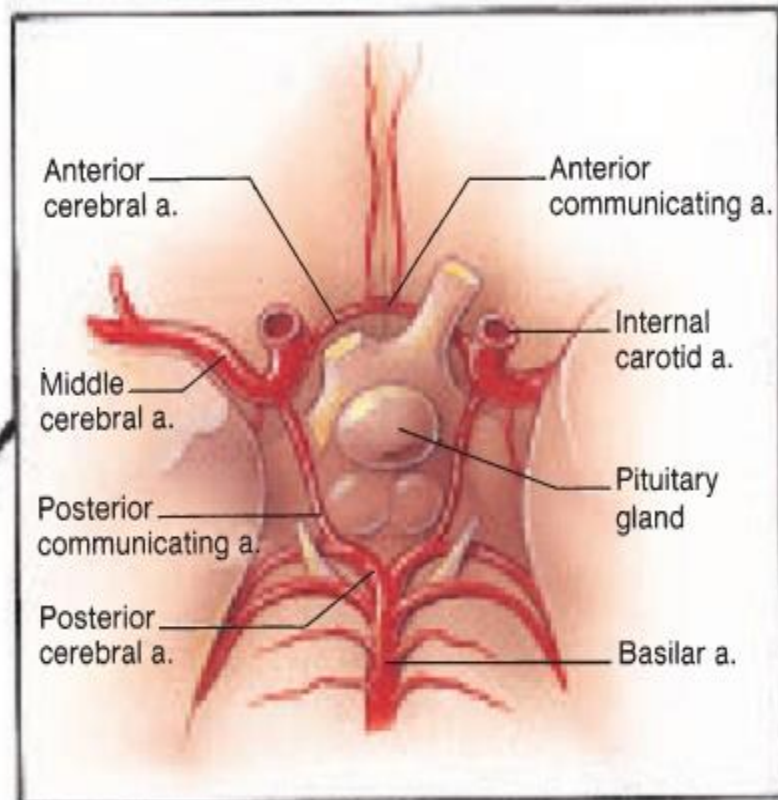
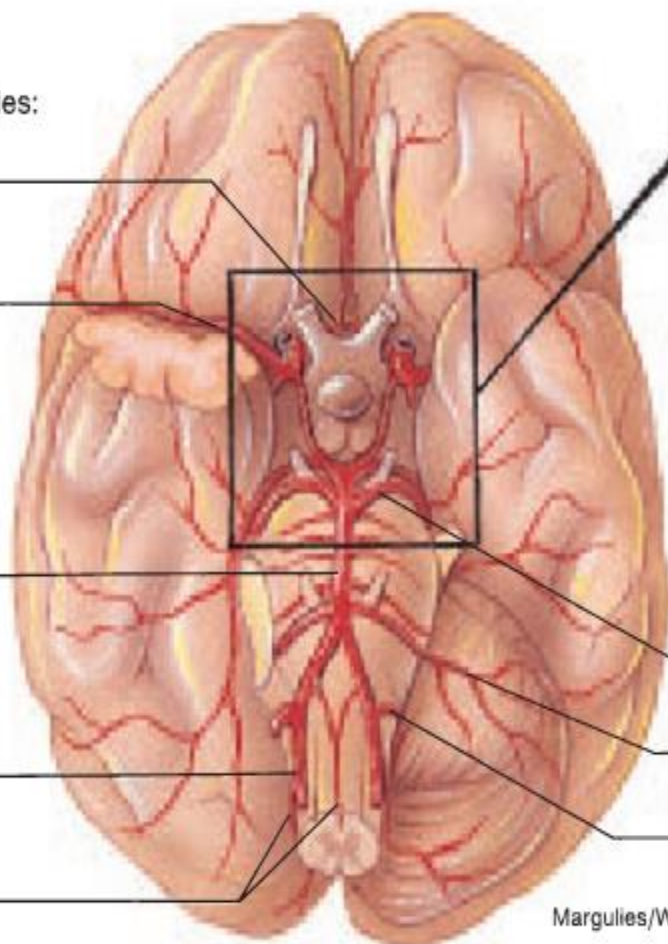
Superior

Anterior inferior

Posterior inferior

Margulies/Waldrop

(a)



ANTERIOR

Cerebral arterial  
circle (circle of Willis):

Anterior  
cerebral

Anterior  
communicating

Internal  
carotid

Posterior  
communicating

Posterior  
cerebral

Frontal lobe  
of cerebrum

Middle cerebral

Temporal lobe  
of cerebrum

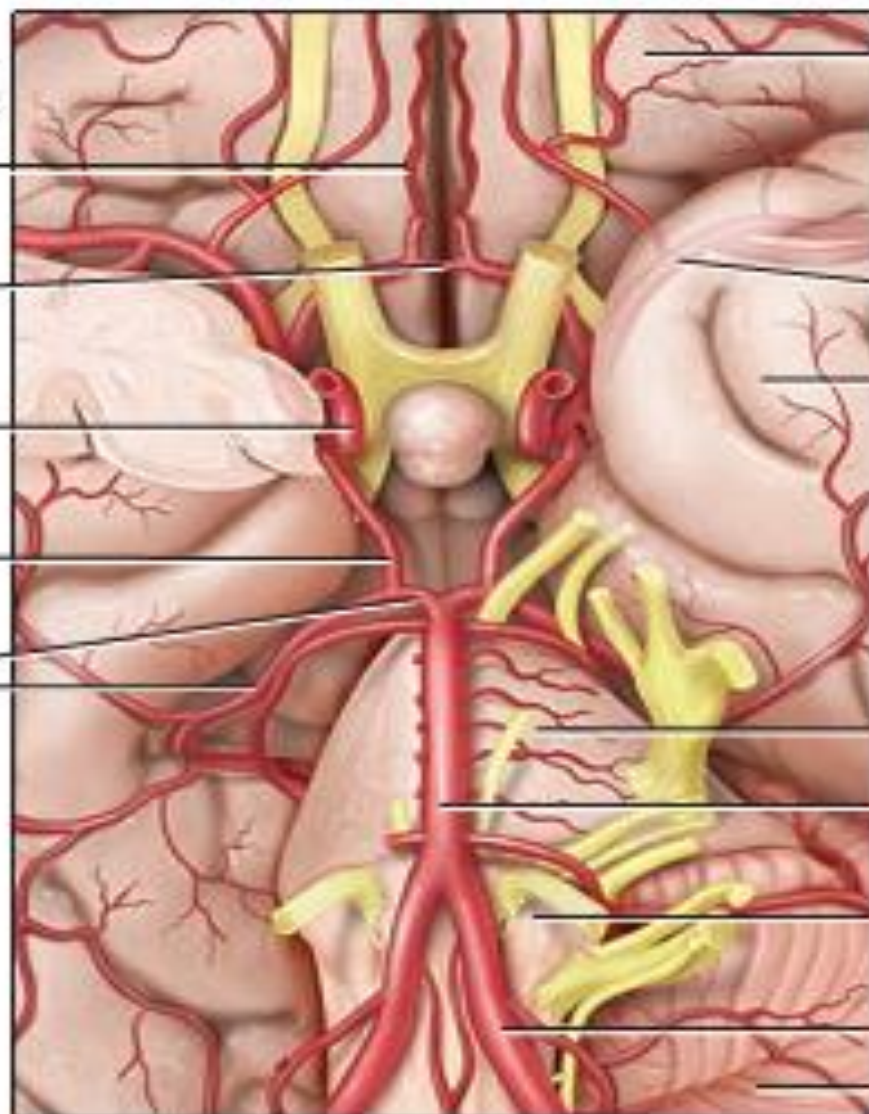
Pons

Basilar

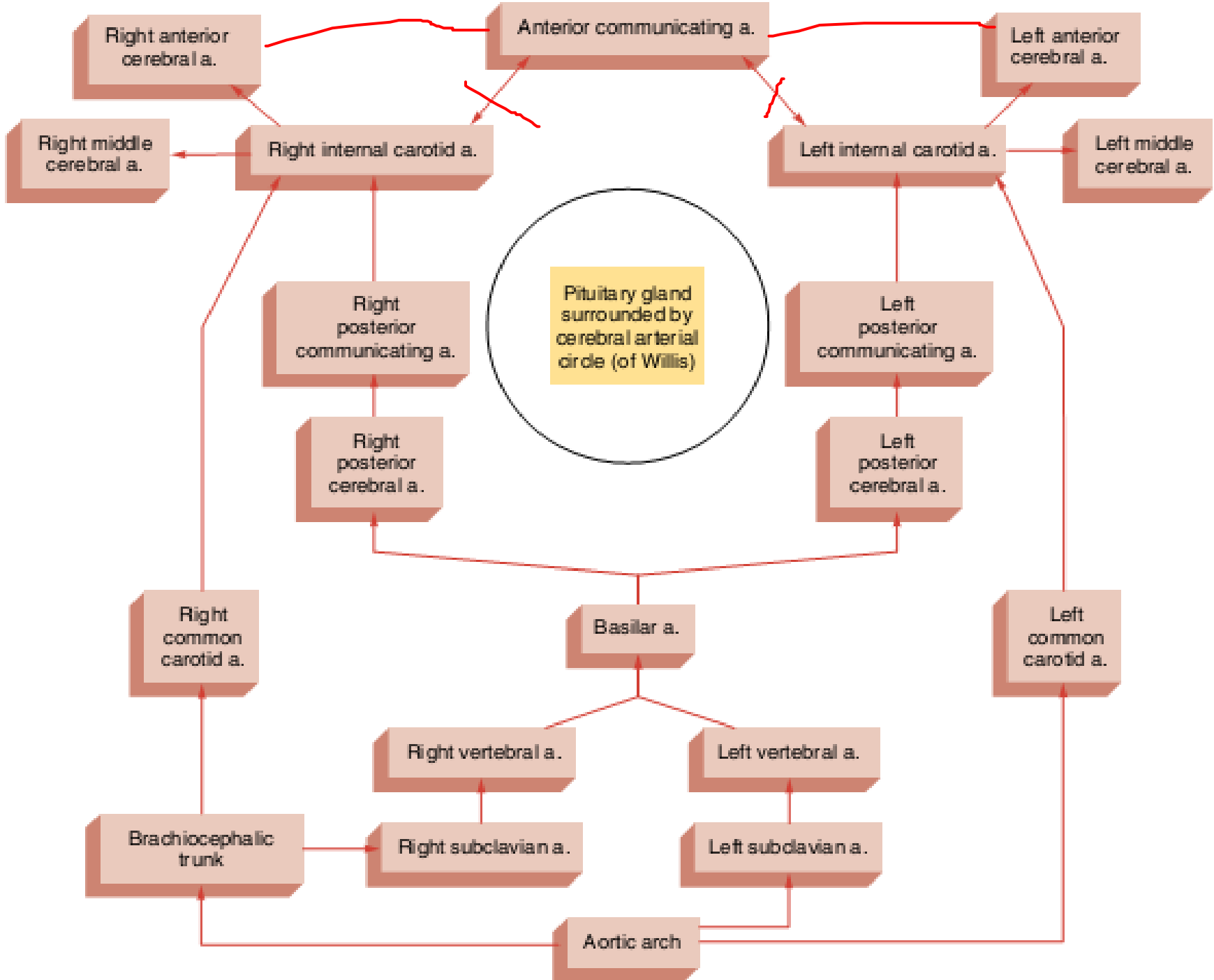
Medulla  
oblongata

Vertebral

Cerebellum

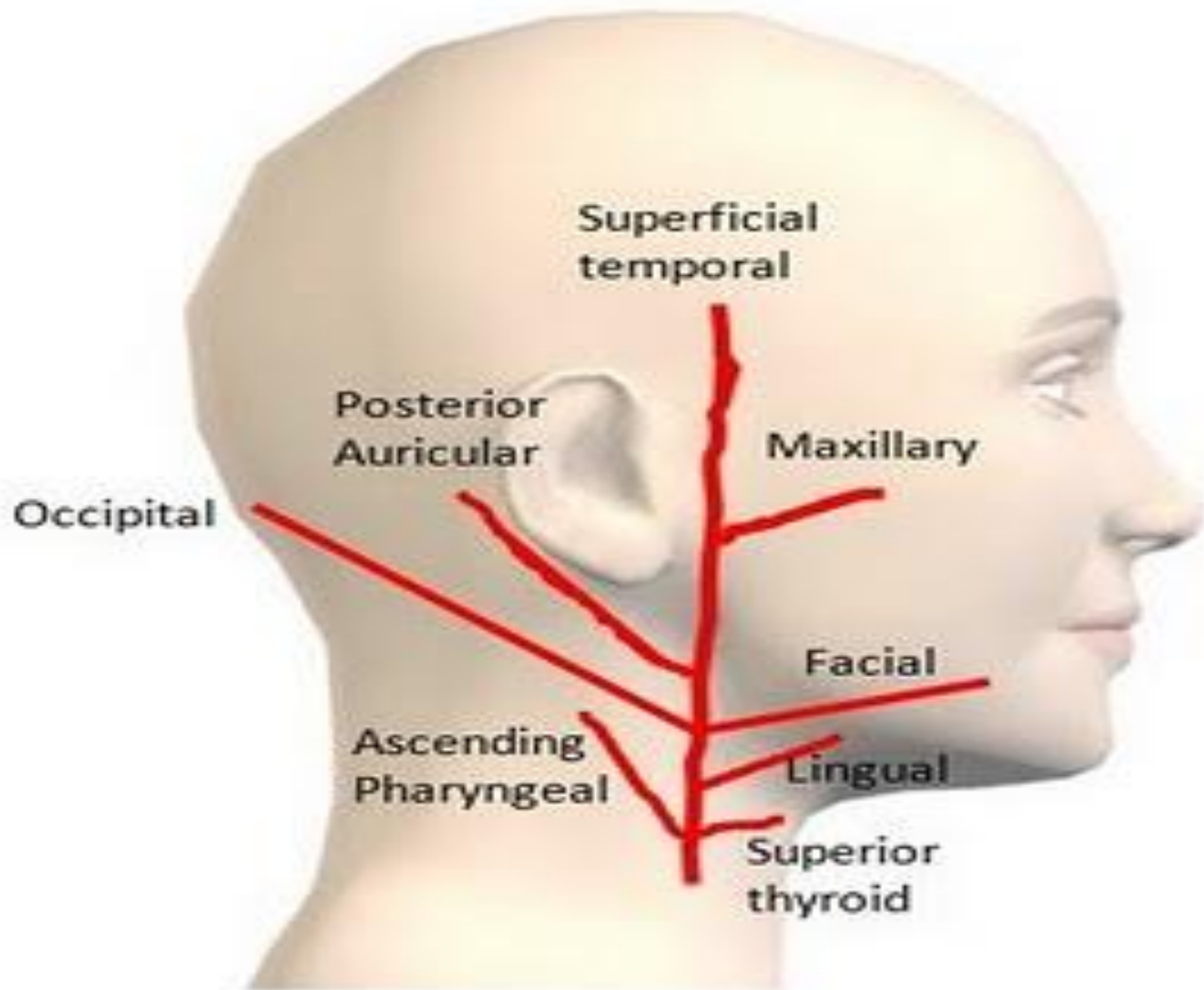


POSTERIOR

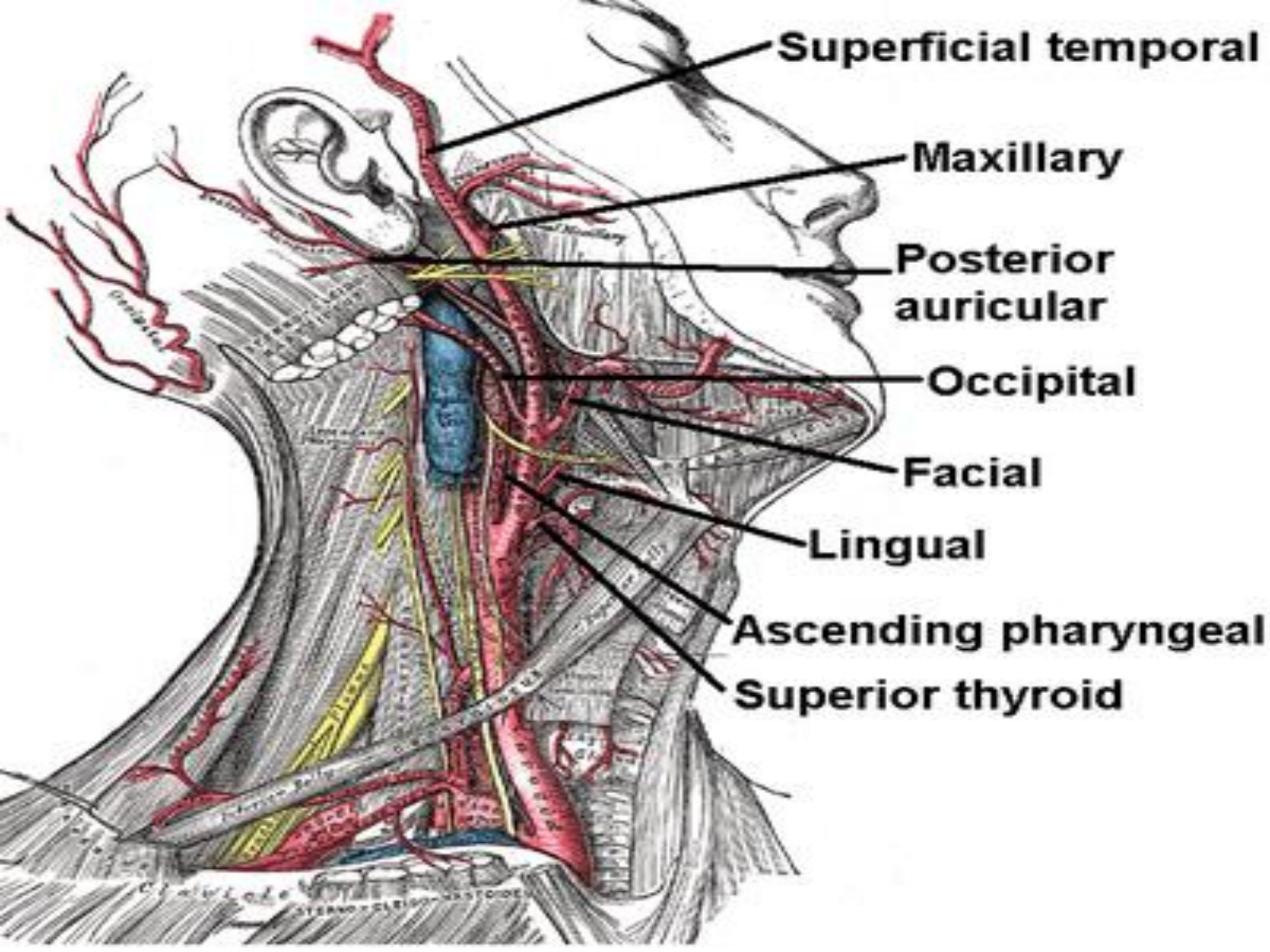


# EXTERNAL CAROTID ARTERIES

- ◉ Major blood source to all structures of head except brain.
- ◉ external carotid artery gives off several branches as it extends upward along the side of the neck and head. These are:
  - **the superior thyroid artery**, which serves the larynx and vocal folds, and the thyroid gland
  - **the lingual artery**, which provides extensive vascularization to the tongue and sublingual gland
  - **the facial artery**, which traverses on inferior margin of the mandible to serve the pharyngeal area, palate, chin, lips, and nasal region
  - **the occipital artery**, which serves the posterior portion of the scalp, the meninges over the brain and certain posterior neck muscles
  - **the posterior auricular artery**, which serves the auricle of the ear and the scalp over the auricle.
- ◉ The external carotid artery terminates at a level near the mandibular condyle by dividing into **maxillary and superficial temporal arteries**.
- ◉ The maxillary artery gives off branches to the teeth and gums, the muscles of mastication, the nasal cavity, the eyelids, and the meninges
- ◉ The superficial temporal artery supplies blood to the parotid gland and to the superficial structures on the side of the head.







**Superficial temporal**

**Maxillary**

**Posterior  
auricular**

**Occipital**

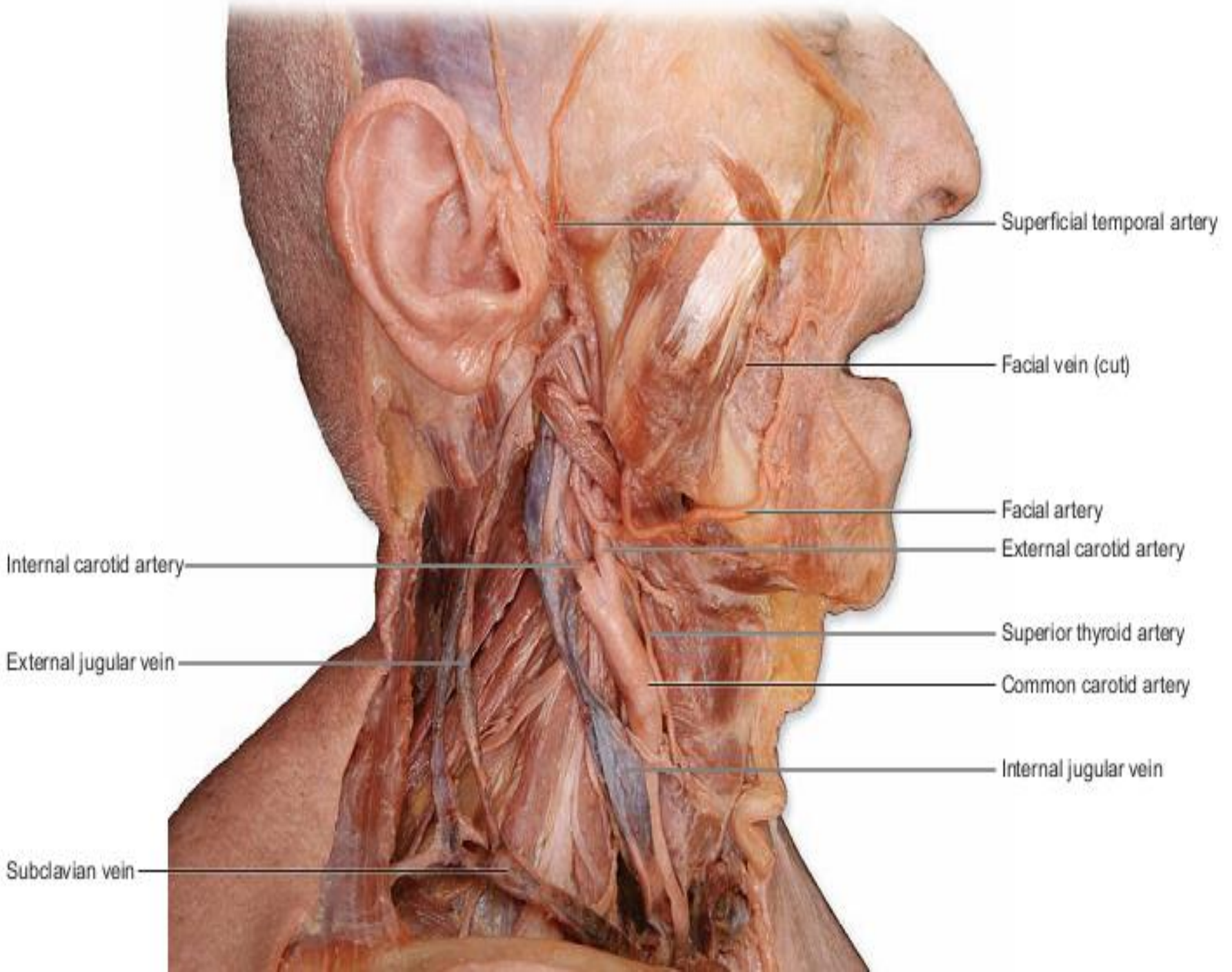
**Facial**

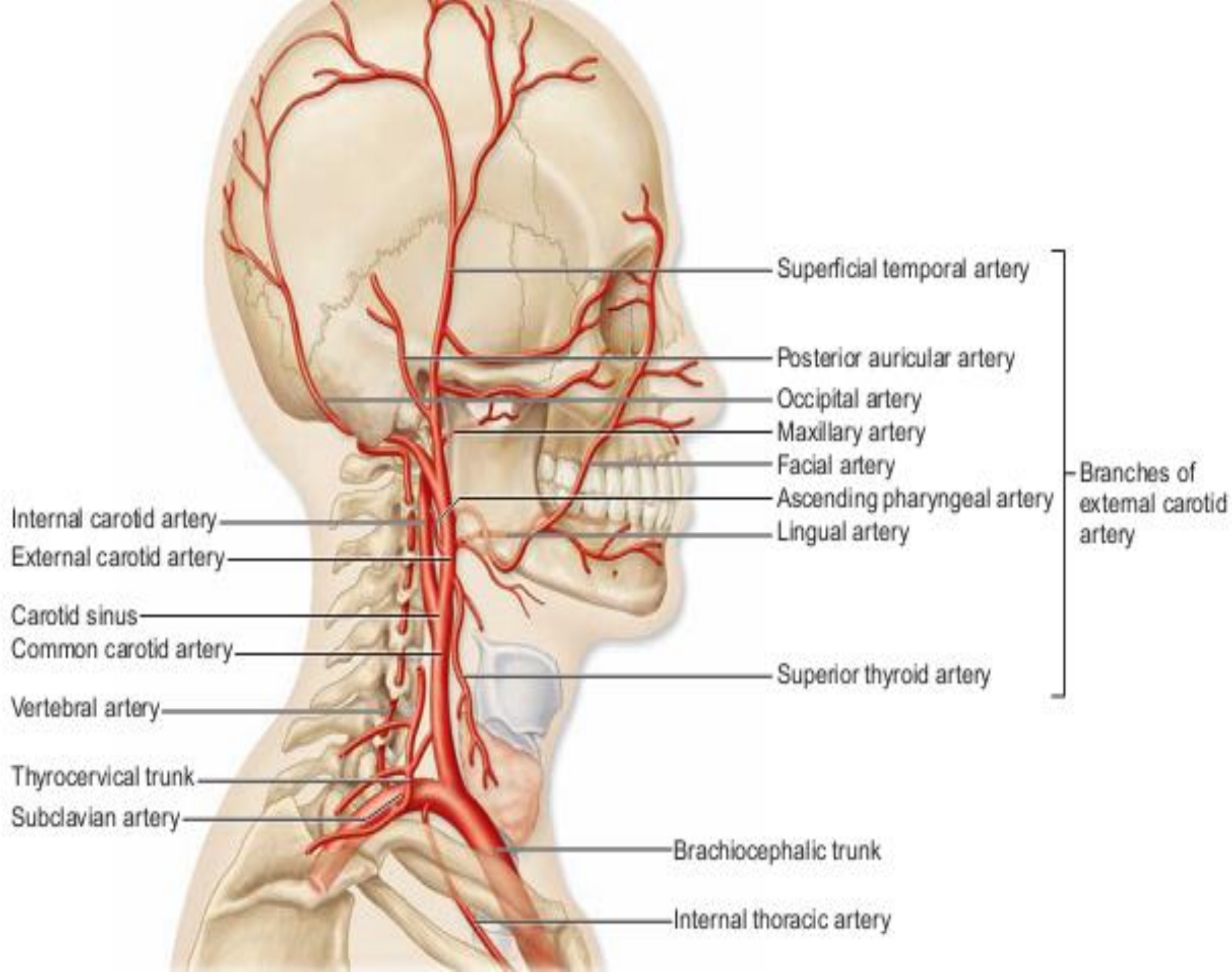
**Lingual**

**Ascending pharyngeal**

**Superior thyroid**







# THORACIC AORTA

- ◉ 20 cm long, continuation of aorta
- ◉ begins at the level of the intervertebral disc between the fourth and fifth thoracic vertebrae, where it lies to the left of the vertebral column.
- ◉ As it descends, it moves closer to the midline and extends through an opening in the diaphragm called aortic hiatus at the level of the intervertebral disc between the twelfth thoracic and first lumbar vertebrae
- ◉ During its course the thoracic aorta gives off numerous branches to viscera (visceral branches) and to wall structures (parietal branches)

# BRANCHES OF THORACIC AORTA

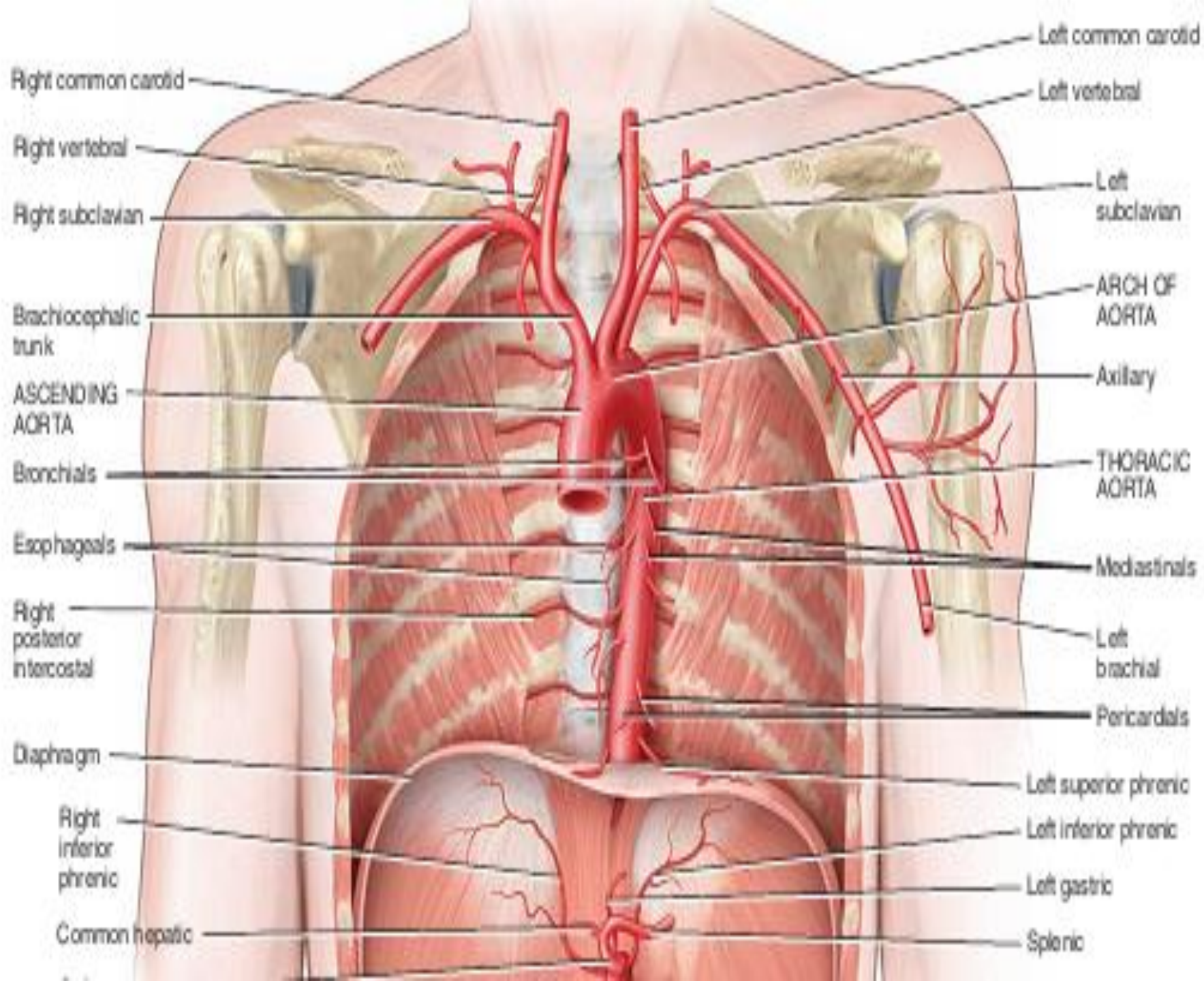
## VISCERAL BRANCHES

- ◉ **Pericardial arteries** arise at various levels of aorta and moves forward to supply the pericardial sac.
- ◉ **Bronchial arteries** arise either directly from aorta or from any of its branch supplies the bronchial.
- ◉ **Esophageal arteries** arise from anterior surface of aorta and supplies all of the esophagus
- ◉ **Mediastinal** arteries arise from various levels of mediastinum and supplies the mediastinal connective tissues and lymph nodes

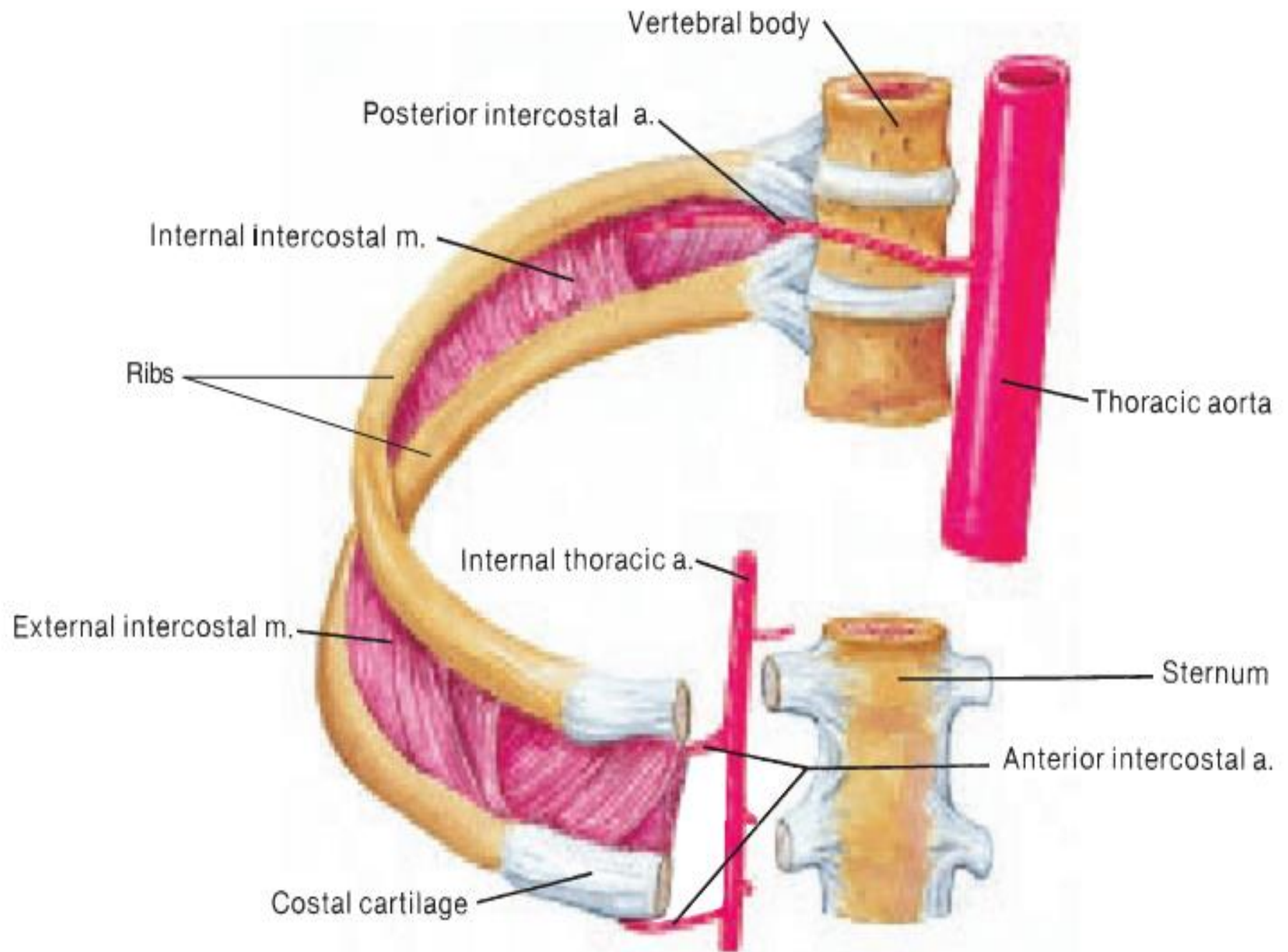


# PARIETAL BRANCHES

- ◉ **Posterior intercostal arteries** nine pairs of arteries that arise from posterolateral aspect on each side of thoracic aorta. Each passes laterally and then anteriorly through intercostal space, where they will eventually anastomose with anterior branches from internal thoracic arteries. Supplies the muscles and ribs of thoracic wall, meninges and spinal cord
- ◉ **Subcostal arteries** arise from lower part of thoracic aorta, extends to lower thoracic wall and upper abdominal body wall. Supplies the skin muscles and ribs of lower thorax and spinal cord and meninges
- ◉ **Superior phrenic arteries** arise from the lower part of thoracic aorta extends to the superior surface of diaphragm supplying the diaphragm muscle and pleura







# ABDOMINAL AORTA

- ◉ The abdominal portion of the aorta is the segment of the aorta **between the diaphragm and the level of the fourth lumbar vertebrae**, where it divides into the right and left common iliac arteries
- ◉ The abdominal aorta lies anterior to vertebral column.
- ◉ It gives off both parietal and visceral branches.

This anatomical illustration shows a posterior view of the abdominal cavity. The diaphragm is at the top, with the inferior vena cava and right adrenal gland visible. The right kidney is shown in its retroperitoneal position. Major blood vessels, including the abdominal aorta and its branches (celiac trunk, superior and inferior mesenteric arteries), are clearly visible. The right renal vein and artery are also shown. The right common, internal, and external iliac vessels are visible at the bottom. The spleen is visible on the left side of the image, and the ureter is shown descending from the right kidney.

Diaphragm

Inferior vena cava

Right adrenal (suprarenal) gland

Right kidney

Superior mesenteric

Right common iliac

Right internal iliac

Right external iliac

Hepatic veins

Esophageal hiatus

Common hepatic

Splenic

Celiac trunk

Right renal

Abdominal aorta

Inferior mesenteric

Ureter

# BRANCHES OF ABDOMINAL AORTA

## ◉ VISCERAL BRANCHES

### □ Unpaired

- ✓ Celiac trunk
- ✓ Superior mesenteric artery
- ✓ Inferior mesenteric artery

### □ Paired

- ✓ Suprarenal arteries
- ✓ Renal arteries
- ✓ Gonadal arteries

## • PARIETAL BRANCHES

### □ Paired

- ✓ Inferior Phrenic arteries
- ✓ Lumbar arteries

### □ Unpaired

- ✓ Median sacral artery

# UNPAIRED VISCERAL BRANCHES

**Celiac trunk:** arise from the ventral aspect of aorta supplies the esophagus (abdominal component), stomach, duodenum and spleen. It gives off three branches:

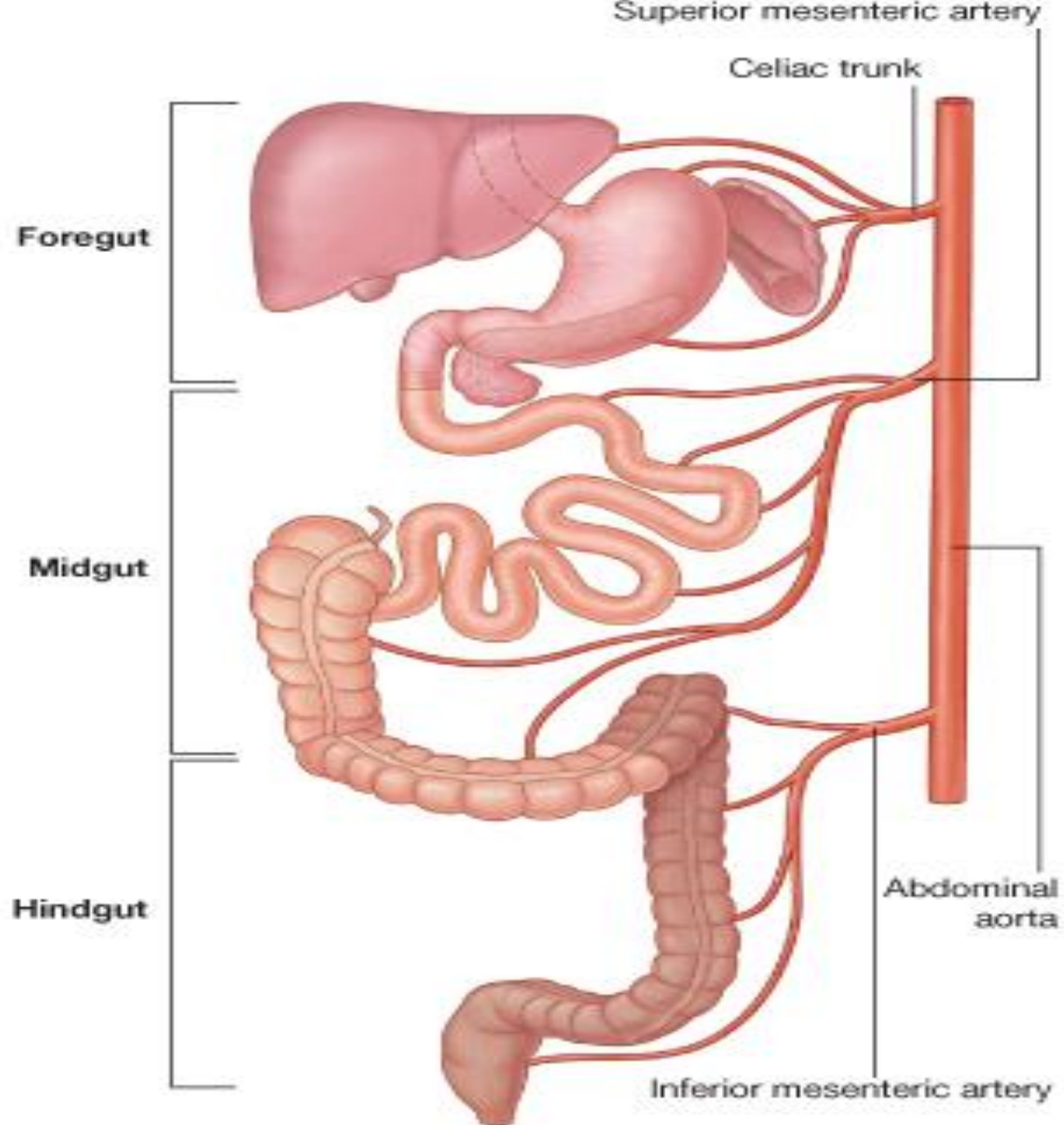
- ❑ **Left gastric artery** supplying the esophagus and stomach
- ❑ **Splenic artery** that gives off branches to spleen, pancreas and stomach (Pancreatic, left gastroepiploic, short gastric)
- ❑ **Common hepatic artery** that gives branches to liver, gallbladder, pancreas and stomach (**proper hepatic, right gastric, gastroduodenal**)

**Superior mesenteric artery:** arise from the ventral surface of abdominal aorta inferior to celiac artery.

- Supplies jejunum, ileum, cecum, appendix, ascending colon, transverse colon and pancreas, through its five branches
- **Inferior pancreaticoduodenal, Jejunal and ileal, ileocolic, right and middle colic**
- Have extensive anastomoses.

**Inferior mesenteric artery:** arise from ventral aspect of aorta inferior to sup. Mesenteric and supplies the large intestine from transverse colon to rectum, through its main three branches (**left colic, sigmoid and rectal**)







# PAIRED VISCERAL BRANCHES

**Suprarenal arteries:** arise from the lateral aspect of aorta

- Mostly three pairs of arteries in which middle arise directly from aorta other two may arise from other branches of abdominal aorta
- Supplies the suprarenal glands ( adrenal glands)

**Renal arteries:** arise from lateral aspect of abdominal aorta supplies the kidneys

**Gonadal arteries:** arise from lateral aspect of aorta just inferior to renal arteries.

- In male they are testicular arteries (passes down the abdominal wall reaching the scrotum)
- In female they are called ovarian arteries

## PAIRED PARIETAL BRANCHES

**Inferior phrenic arteries:** arise from lateral aspect of aorta superior to celiac trunk, supplies the diaphragm

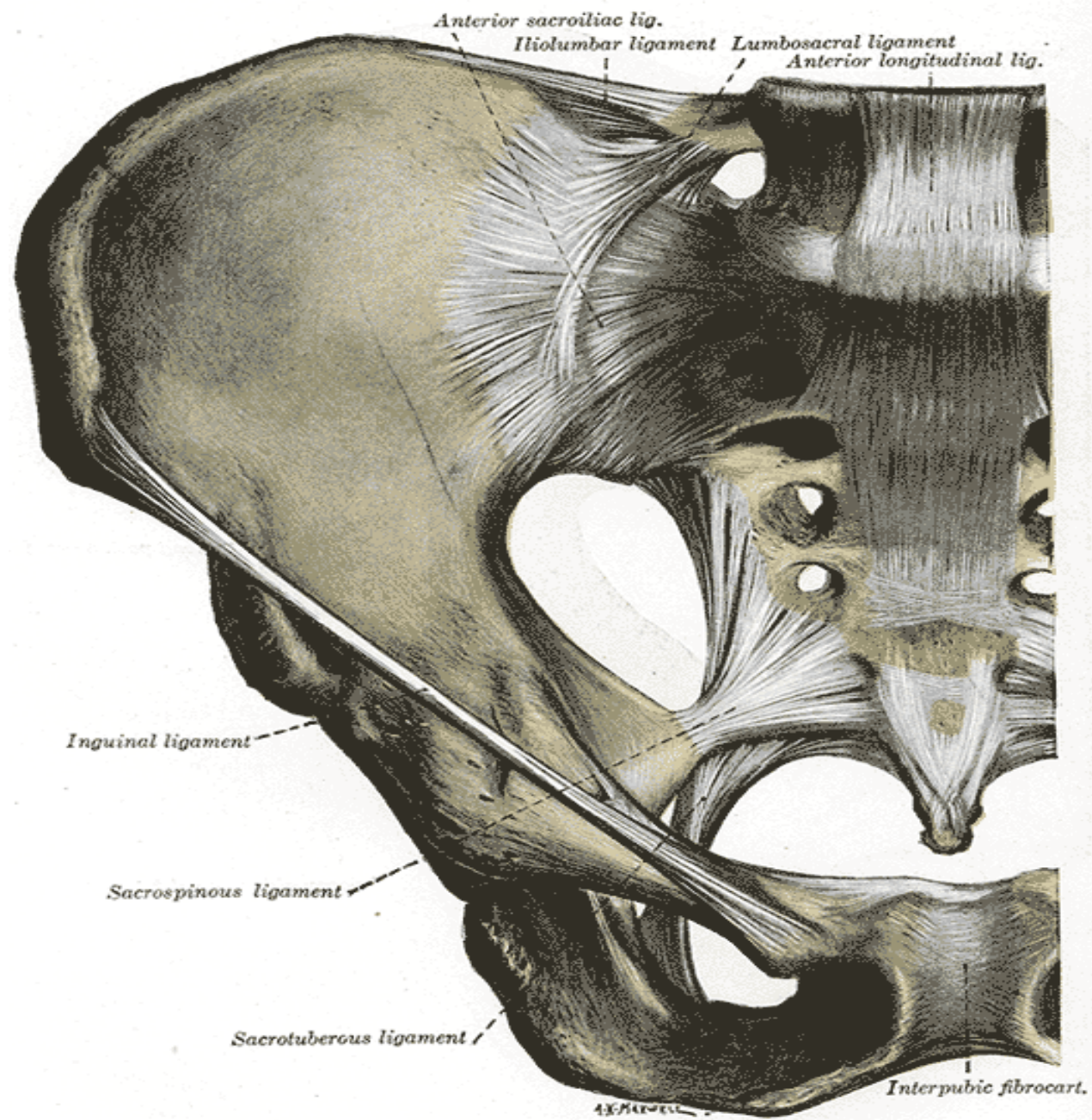
**Lumbar arteries:** arise from dorsal (postereolateral) aspect of aorta supplies the lumbar vertebrae, spinal cord and muscles of abdominal wall.

## UNPAIRED PARIETAL BRANCHES

**Median sacral artery** arise from the dorsal aspect of aorta supplies the sacral and coccyx vertebrae and spinal nerves

# ILIAC ARTERIES

- ◉ At posterior pelvic area the abdominal aorta bifurcates to right and left iliac arteries
- ◉ The iliac arteries go down the pelvis and terminates by dividing into internal and external iliac arteries
- ◉ The internal iliac arteries branch extensively and supplies the gluteal muscles and pelvic organs (important branches are gluteal iliolumbar, gluteal, vesicular, uterine and vaginal, pudendal arteries)
- ◉ The external iliac arteries passes out of pelvic cavity deep to the inguinal ligament and become femoral arteries

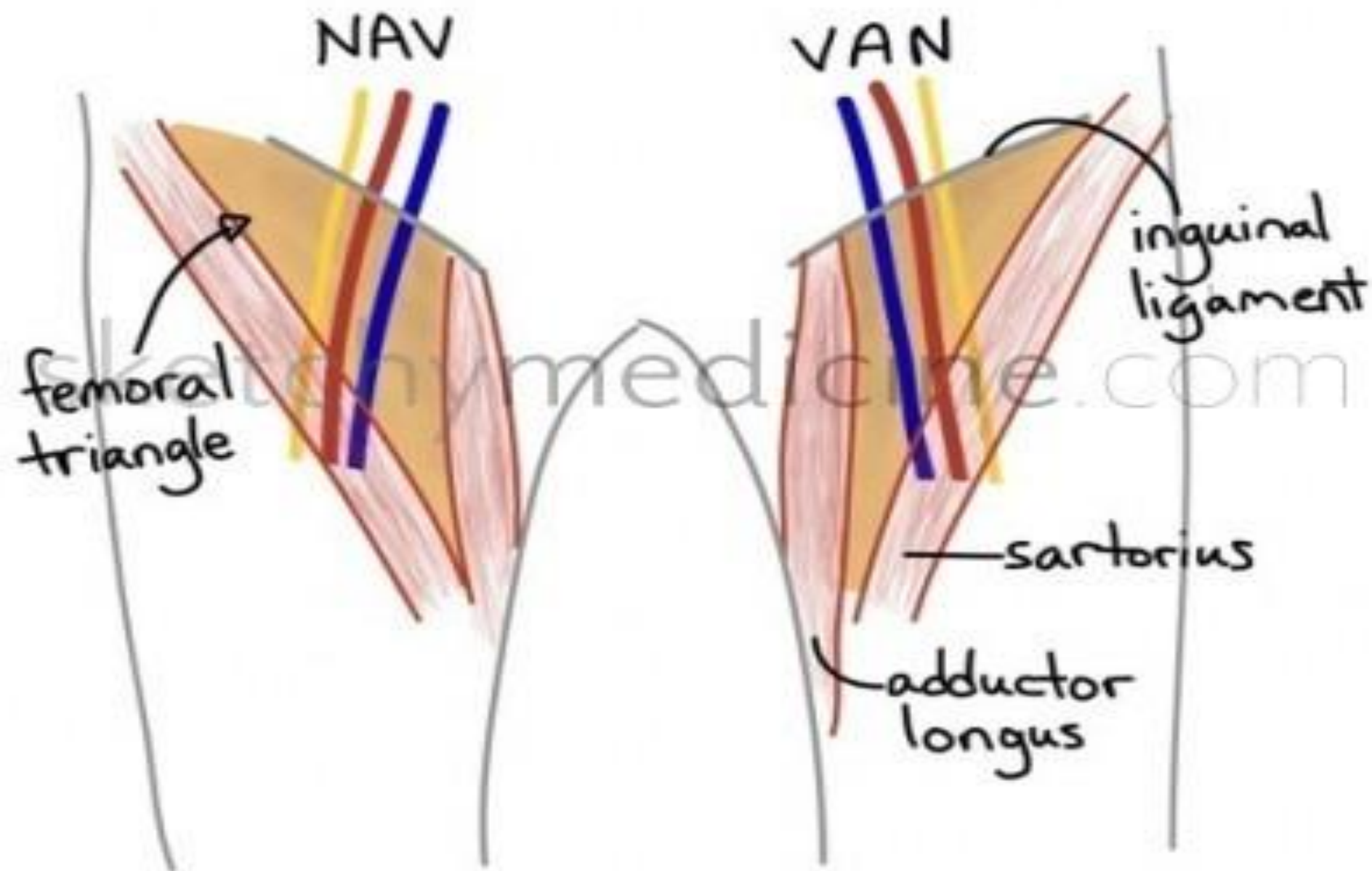


# FEMORAL ARTERY

- ◉ The femoral artery passes through the **femoral triangle** where it become superficial and it can be palpated
- ◉ It passes downwards and posteriorly to knee where it is called **popliteal artery**.
- ◉ The popliteal artery gives off small branches to knee joint and then divides to **anterior tibial artery and posterior tibial artery**.
- ◉ The anterior tibial artery runs on the anterior aspect of leg supplying the foot muscles.
- ◉ At ankle it becomes **dorsal pedal artery** which supplies the ankle and dorsum
- ◉ It can be palpated there and is the most distal pulse of the body

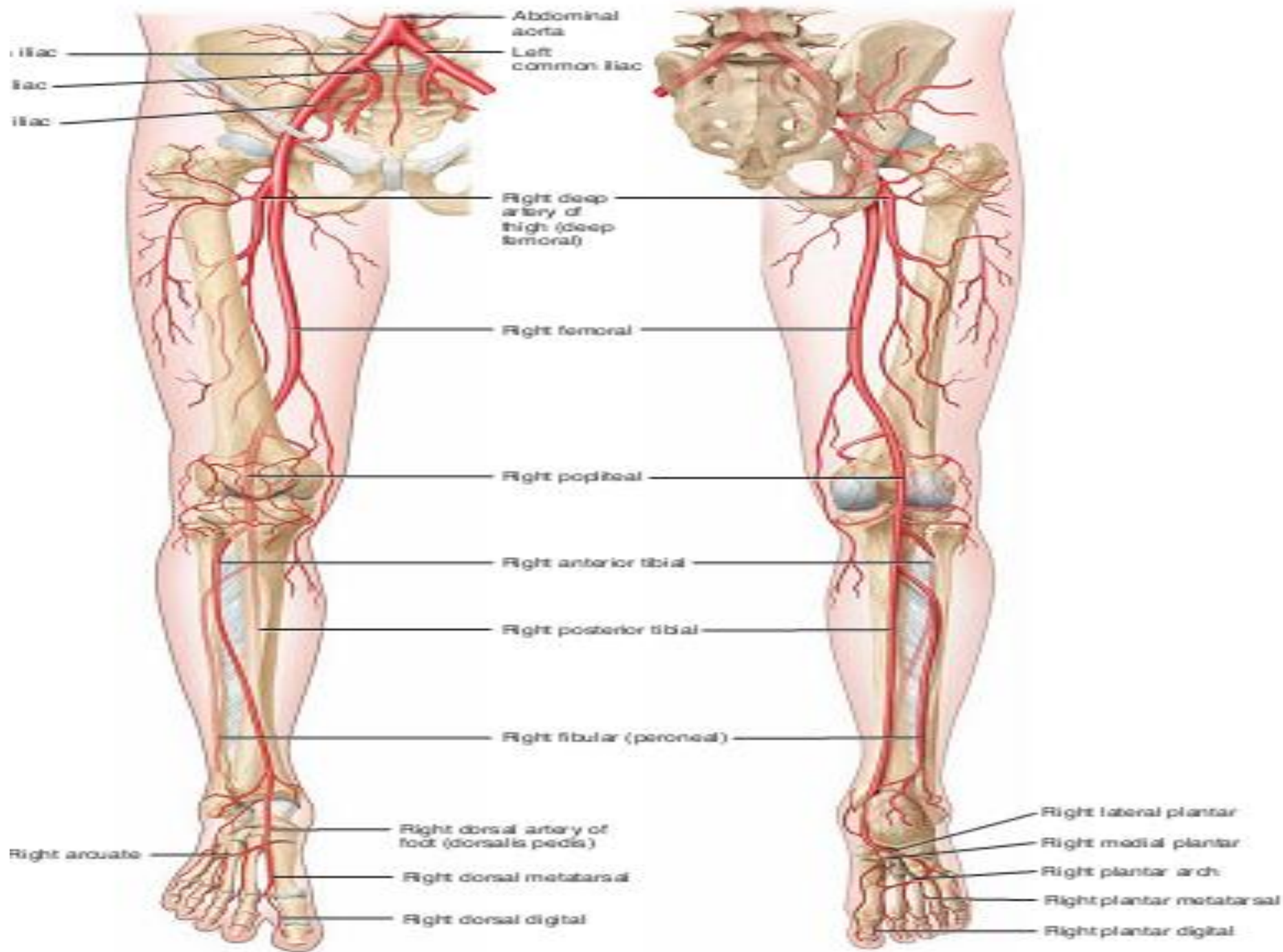


# FEMORAL TRIANGLE





- The posterior tibial artery runs on the posterior aspect of leg, at the ankle it divides into lateral plantar artery and medial plantar artery
- The lateral plantar artery anastomose with dorsal pedal artery making plantar arch which gives off digital arteries to the toes



(a) Anterior view

(b) Posterior view

# VENOUS SYSTEM

- ◉ Collect blood from the body
- ◉ All veins converge to form two large vessels called venacava which drains deoxygenated blood into right atrium.
- ◉ Veins can be both deep and superficial
- ◉ Superficial veins can be seen beneath the skin and are used for venipuncture.
- ◉ Deep veins run parallel to arteries and are named according to the corresponding artery or the organ they serve

# VEINS OF UPPER EXTREMITY

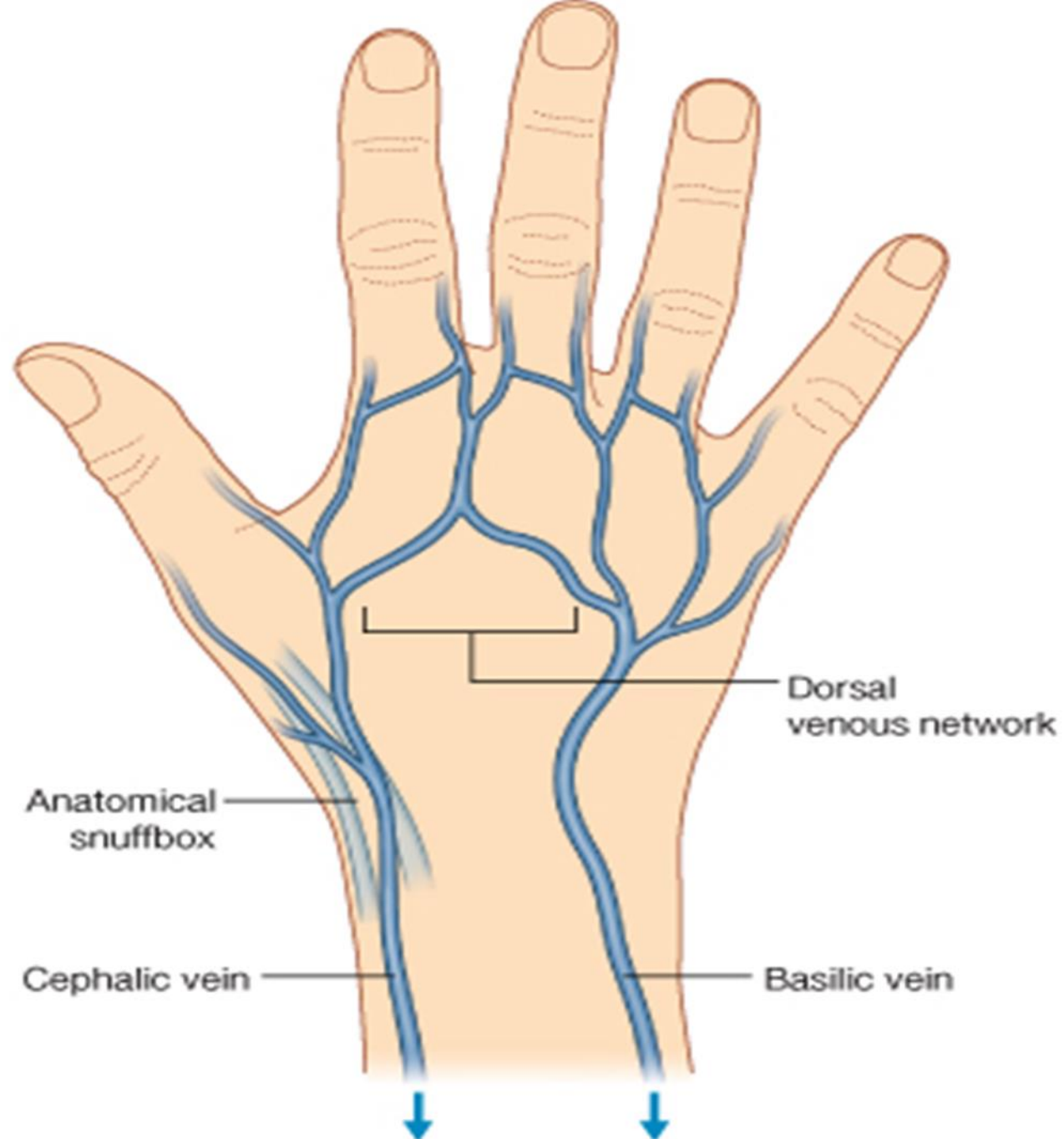
- ◉ Two types
  - ❑ Superficial
  - ❑ Deep veins
- ◉ Deep veins
  - ❑ **radial and ulnar veins**
  - ❑ Radial runs on the lateral side of the forearm
  - ❑ Ulnar runs on the medial side
  - ❑ Drains blood from the palmar arches
  - ❑ Combine to form **brachial vein** at cubital fossa
  - ❑ Brachial runs on the medial side of brachium
  - ❑ Brachial vein becomes axillary vein at the axillary region
  - ❑ Beneath the clavicle it is known as **subclavian vein**

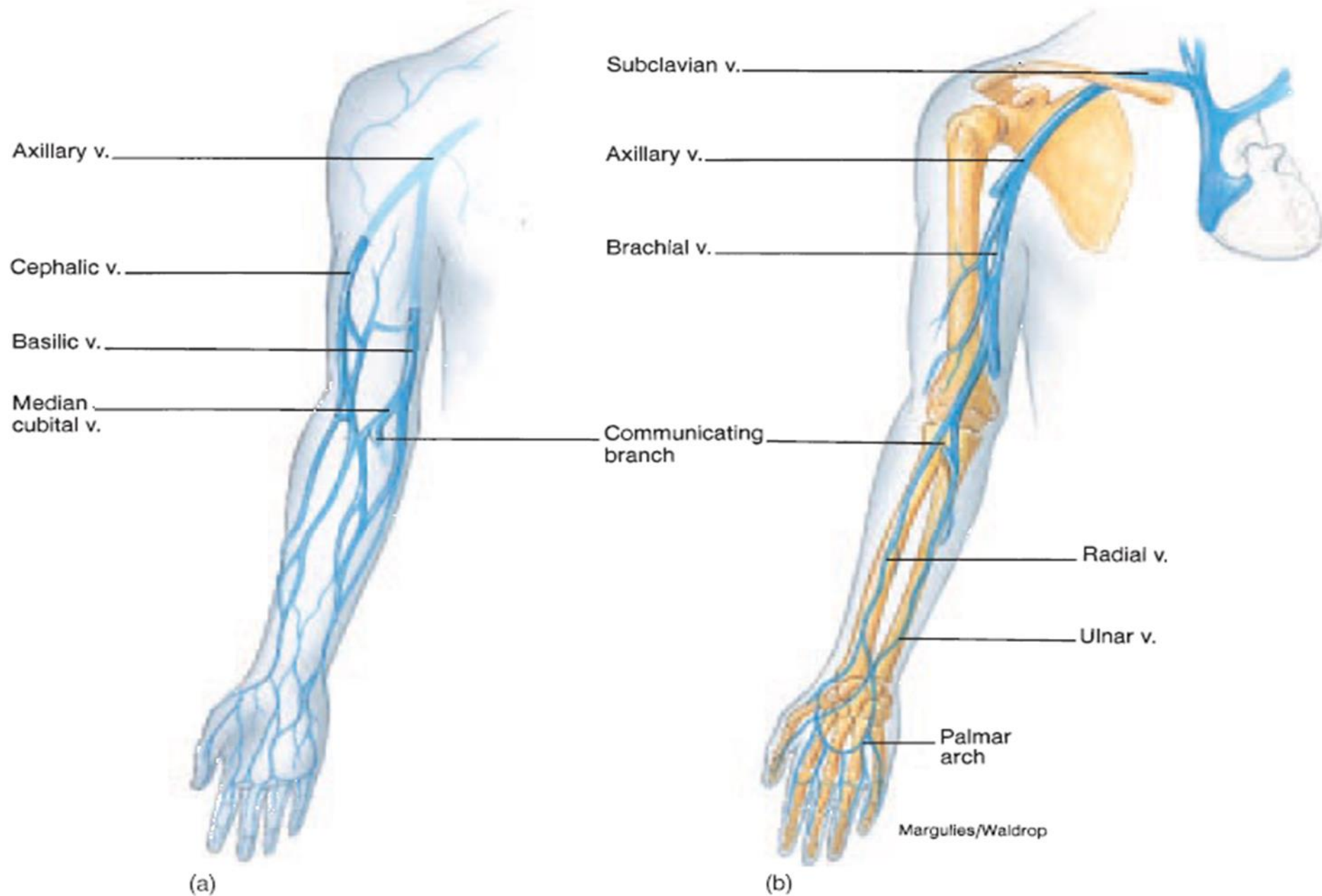
## ◉ **Superficial veins**

Collect blood from the dorsal venous arches of hand

- ❑ **Basilic vein** runs on the ulnar / medial side of the forearm and arm. Join the brachial vein near the head of humerus
- ❑ **Cephalic vein** runs on the radial / lateral side of the forearm and arm. Join the axillary vein at shoulder region
- ❑ **Median cubital vein** arise from cephalic vein, crosses the cubital fossa running from lateral to medial side. Join the basilic vein (anastomosing the cephalic and basilic veins)







**E 16.36** An anterior view of the veins that drain the upper right extremity. (a) Superficial veins and (b) deep veins.

# VEINS OF THE HEAD AND NECK

## ◉ External jugular veins

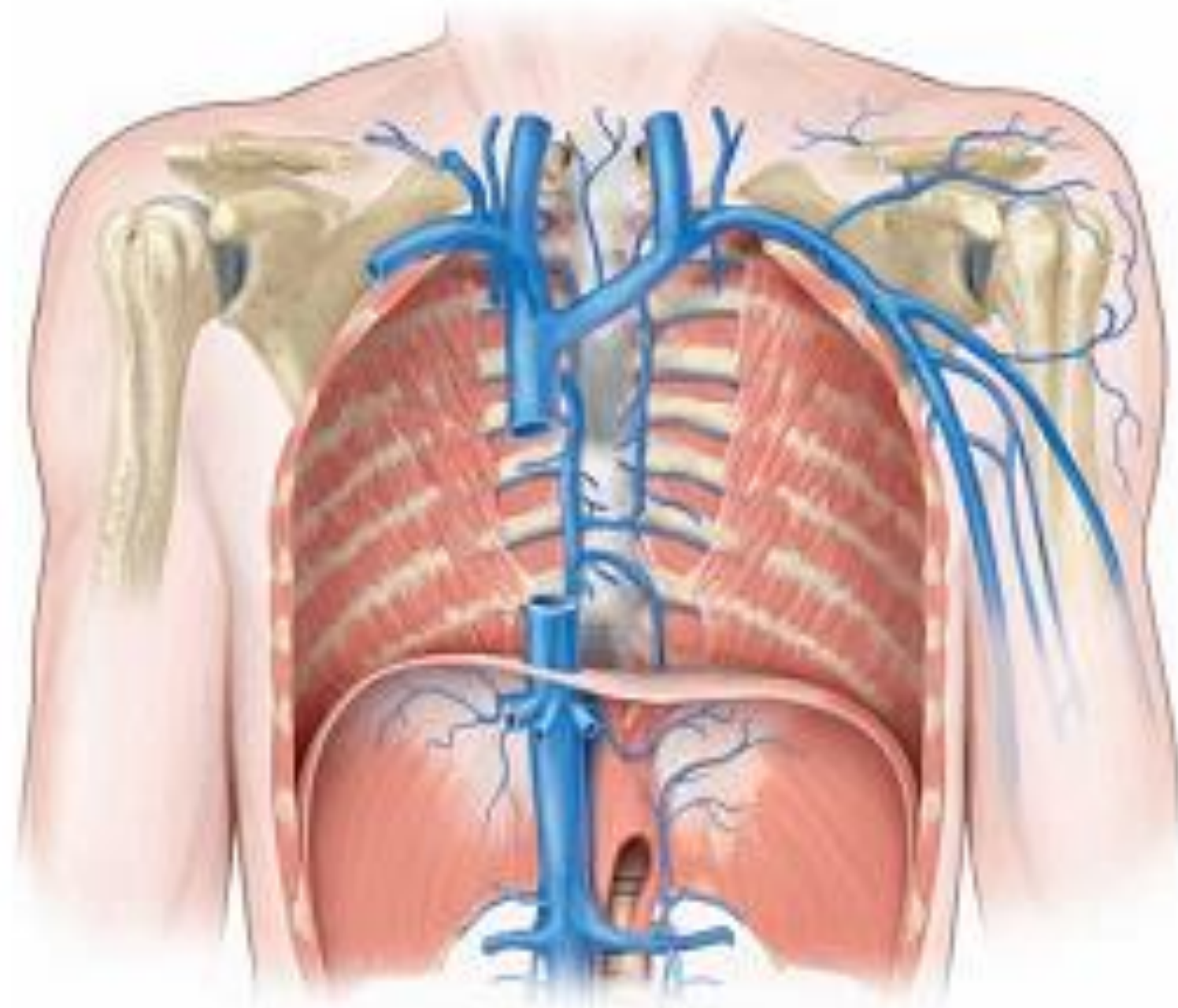
- ❑ Paired veins, collects blood from the scalp, face and superficial neck region.
- ❑ Opens into subclavian veins on the respective side just beneath the clavicle

## ◉ Internal jugular veins

- ❑ Paired veins, collects blood from the brain (collect blood from venous sinuses which in turn collect blood from cerebral, meningeal, ophthalmic and cerebellar arteries), deep face structures and portion of neck
- ❑ Passes inferiorly down the neck, adjacent to the common carotid artery, joins the subclavian vein making a large **brachiocephalic vein** on each side

# SUPERIOR VENACAVA

- ◉ The two brachiocephalic vein join to form superior venacava at right 1<sup>st</sup> costal cartilage
- ◉ Valveless vein, about 7.5 cm long and 2 cm in diameter
- ◉ Also collect blood from the thorax and posterior abdominal from the azygous vein
- ◉ Empties deoxygenated blood from the upper body into right atrium





# VEINS OF THE LOWER EXTREMITY

- ◉ The lower extremities, like the upper extremities, have both deep and superficial veins.
- ◉ The deep veins accompany corresponding arteries and have more valves than do the superficial veins.

## **Deep veins:**

- ◉ posterior and anterior tibial veins.
- ◉ Originate in the foot and course upward behind (posterior tibial vein) and in front of the tibia (anterior tibial vein) to the back of the knee.
- ◉ In the knee they merge to form the popliteal vein.
- ◉ The popliteal vein receives blood from the knee region.
- ◉ Just above the knee, this vessel becomes the femoral vein.

- ◉ The femoral vein in turn continues up the thigh and receives blood from the deep femoral vein near the groin.
- ◉ Just above this point, the femoral vein receives blood from the great saphenous *vein*
- ◉ becomes the **external iliac vein** as it passes under the inguinal ligament.
- ◉ The external iliac curves upward to the level of the sacroiliac joint, where it merges with the internal iliac vein at the pelvic and genital regions to form the **common iliac vein**.
- ◉ At the level of the fifth lumbar vertebra, the right and left common iliacs unite to form the large **inferior vena cava**.

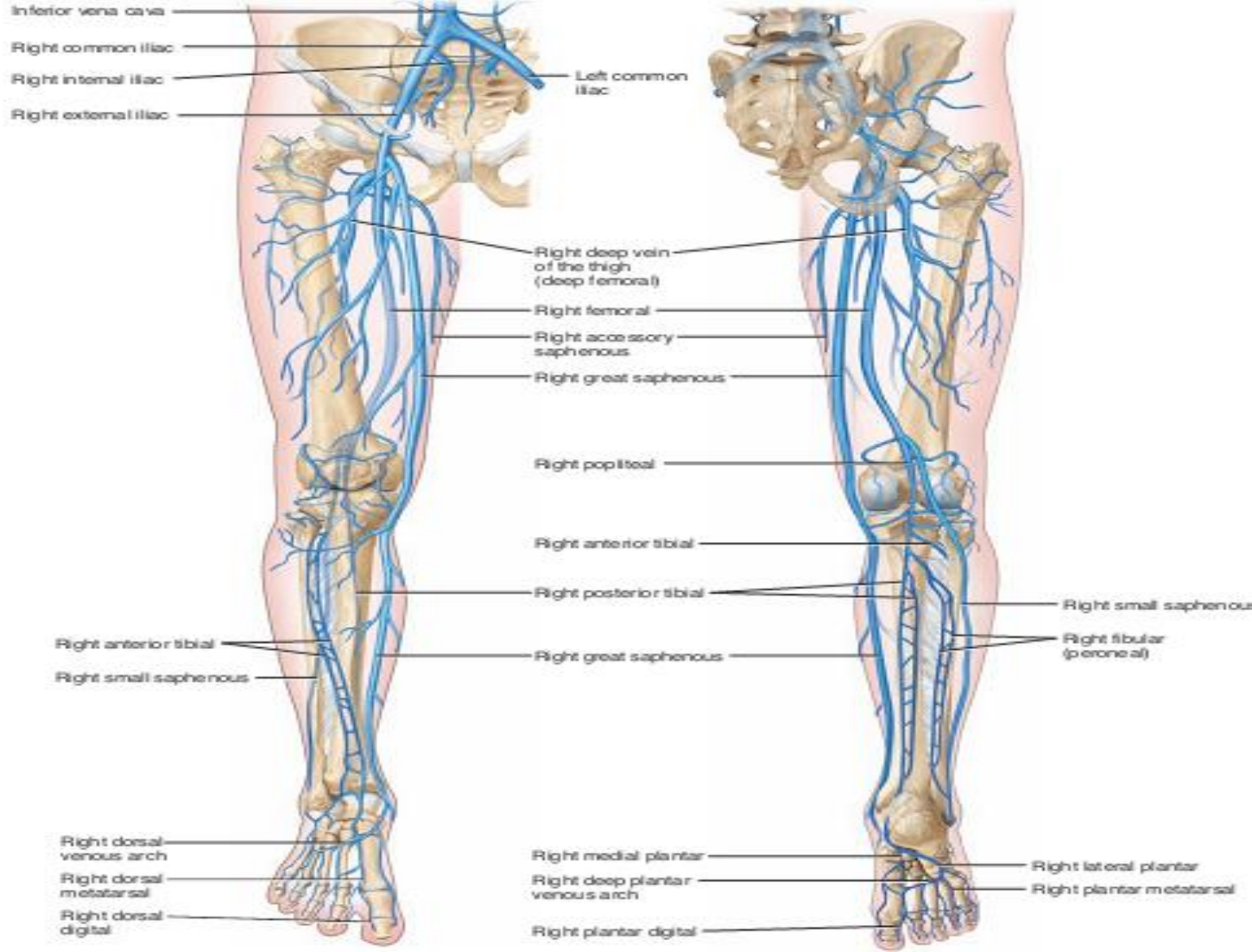
## ◎ Superficial veins

### ❑ Great saphenous vein:

- ✓ Largest vein in the body (starts from foot end at groin)
- ✓ It originates from the medial side of the foot and ascends along the medial aspect of the leg and thigh before emptying into the femoral vein
- ✓ Collect blood from dorsal venous arches of foot, superficial tissues and also have connections with deep veins
- ✓ Have 10 to 20 valves but poorly supported by skeletal muscles
- ✓ Site for prolong administration of I/V fluids and I/V administration in children
- ✓ Used for CABG surgery

### ❑ Small saphenous vein

- ✓ The small saphenous vein arises from the lateral side of the foot and ascends deep to the skin along the posterior aspect of the leg.
- ✓ It empties into the popliteal vein, posterior to the knee.

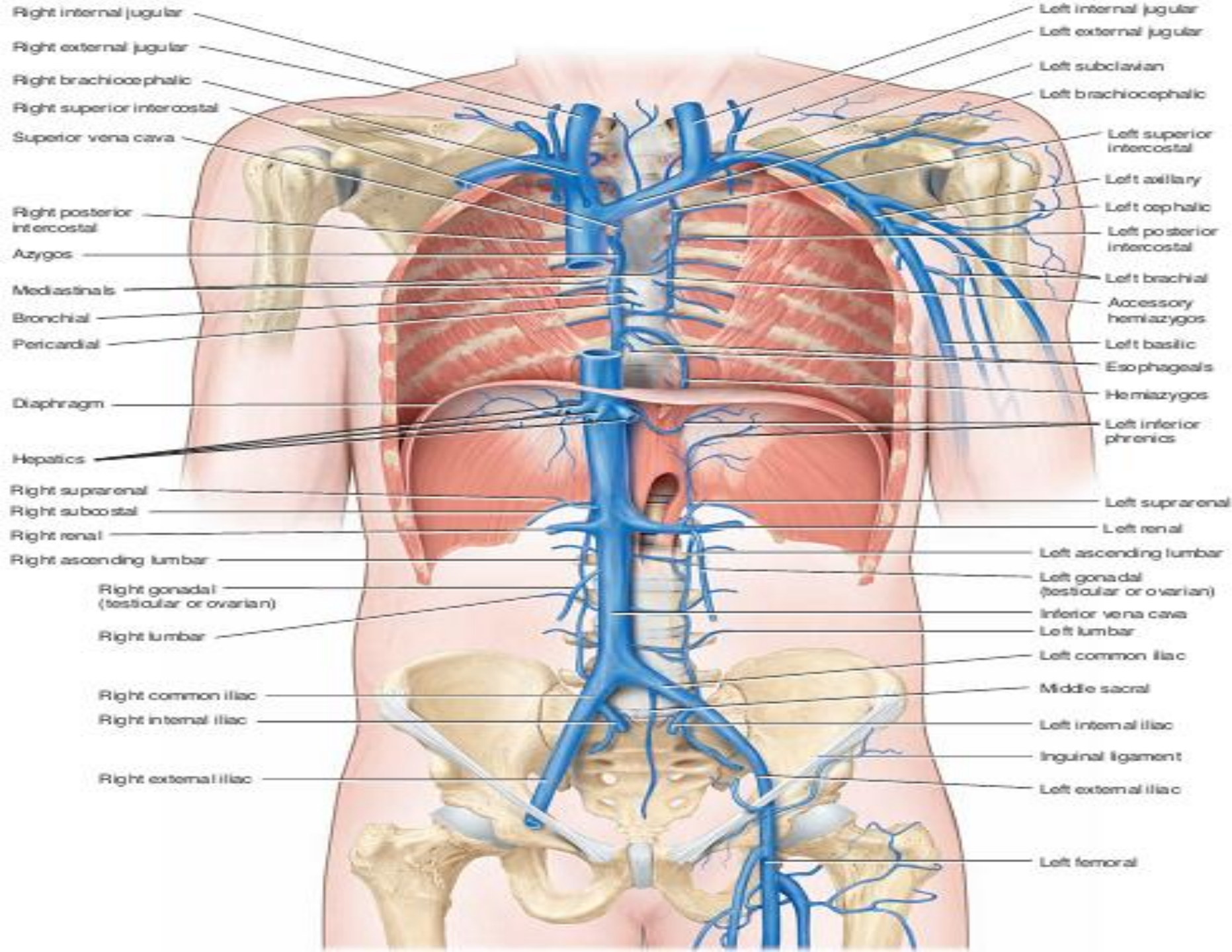


# VEINS OF THE ABDOMEN

## ○ Inferior vena cava

- **parallels the abdominal aorta on the right side** as it ascends through the abdominal cavity to penetrate the diaphragm through caval opening at eighth thoracic vertebra and enter the right atrium.
  - It is the largest vessel in body (3.5cm diameter) and is formed by the union of the two common iliac veins that drain the lower extremities.
- 
- As it passes through abdominal cavity the inferior vena cava receives the blood from the following veins.
  - **Four paired lumbar veins** drain the posterior abdominal wall, the vertebral column, and the spinal cord.
  - **The renal veins** drain blood from the kidneys and ureters into the inferior vena cava.
  - **The right testicular vein** in males (or the right ovarian vein in females) drains the corresponding gonads.
  - **The right suprarenal vein** drains the right adrenal gland. These veins empty into the inferior vena cava.
  - **The left testicular vein (or left ovarian vein) and the left suprarenal vein**, by contrast, empty into the left renal vein.
  - **The inferior phrenic veins** receive blood from the inferior side of the diaphragm and empty into the inferior vena cava.
  - **Right and left hepatic veins** originate from the capillary sinusoids of the liver and empty into the inferior vena cava immediately below the diaphragm





# FETAL CIRCULATION

- ◉ The fetus has four circulatory features that are not present in adult circulation.
  1. The **foramen ovale**, or oval window, is an opening between the two atria. This window is covered by a flap of tissue that acts as a valve.
  2. The **ductus arteriosus**, or arterial duct, is a connection between the pulmonary artery and the aorta.
  3. The **umbilical arteries and vein** are vessels that travel to and from the placenta, leaving waste and receiving nutrients.
  4. The **ductus venosus**, or venous duct, is a connection between the umbilical vein and the inferior vena cava.

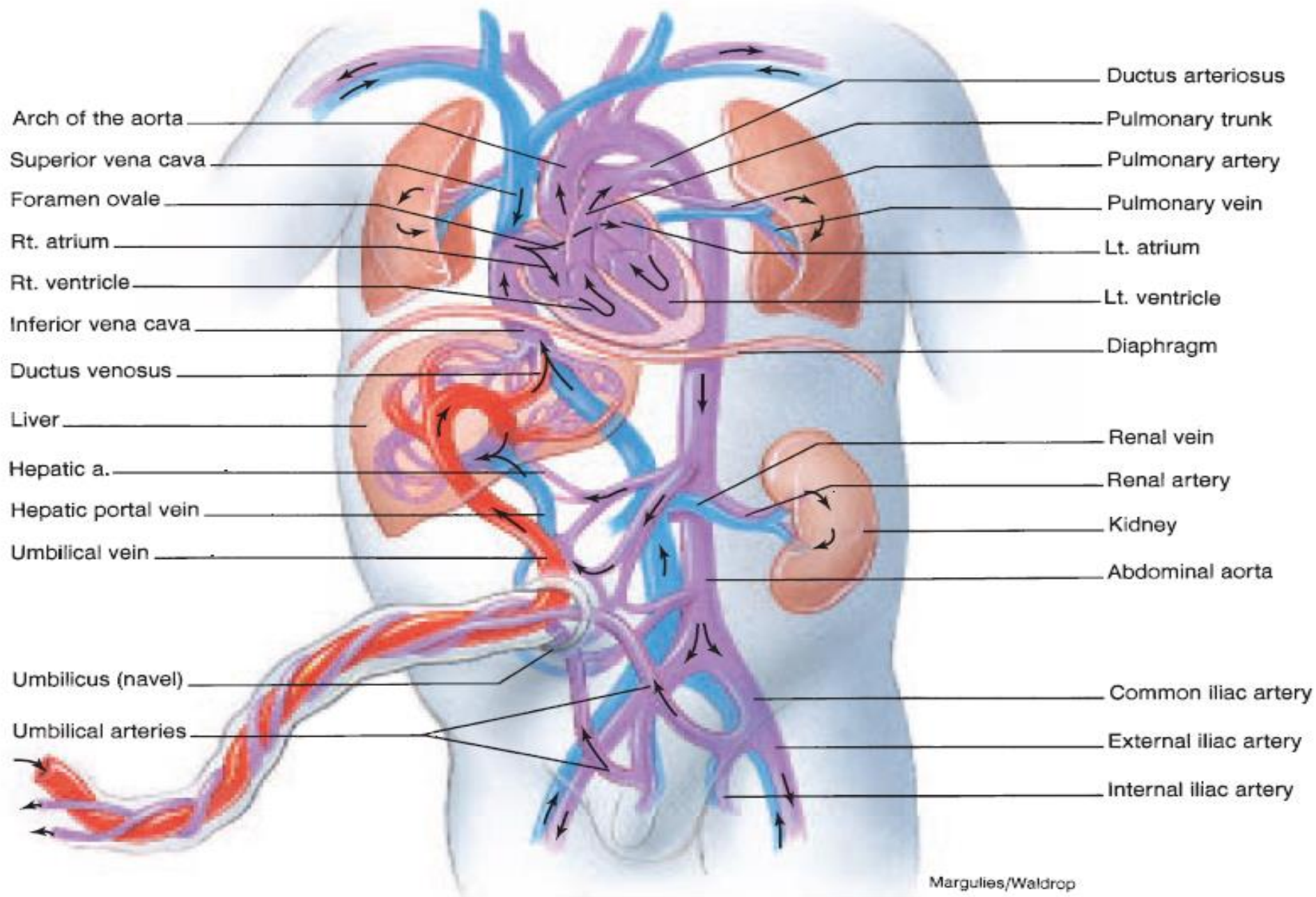
- Fetus receives the nutrients and oxygen from the umbilical cord which is connection between the placenta and the fetal umbilicus.
- It includes one umbilical vein and two umbilical arteries, surrounded by a gelatinous substance.
- Oxygenated and nutrient-rich blood flows through the umbilical vein toward the inferior surface of the liver.
- At this point, the umbilical vein divides into two branches. One branch merges with the portal vein, and the other branch, called the ductus venosus enters the inferior vena cava.
- Thus, oxygenated blood is mixed with venous blood returning from the lower extremities of the fetus before it enters the heart.
- The umbilical vein is the only vessel of the fetus that carries fully oxygenated blood.

- ◉ The inferior vena cava empties into the right atrium of the fetal heart bringing oxygen rich blood.
- ◉ The superior venacava bring deoxygenated blood from upper body to the right atrium
- ◉ Because of high pressure in the pulmonary artery the blood cannot be conveniently pumped into right ventricle instead only small amount of blood enter the right ventricle and moves into the pulmonary artery
- ◉ Most of the blood passes from the right atrium into the left atrium through the **foramen ovale** , *an* opening between the two atria
- ◉ It then passes into the left ventricle, from where it is pumped into the aorta to the body of the fetus.
- ◉ The blood which entered the pulmonary circulation from the right ventricle faces resistance because of non-functional fetal lungs(the resistance to blood flow is very high in the collapsed fetal lungs).

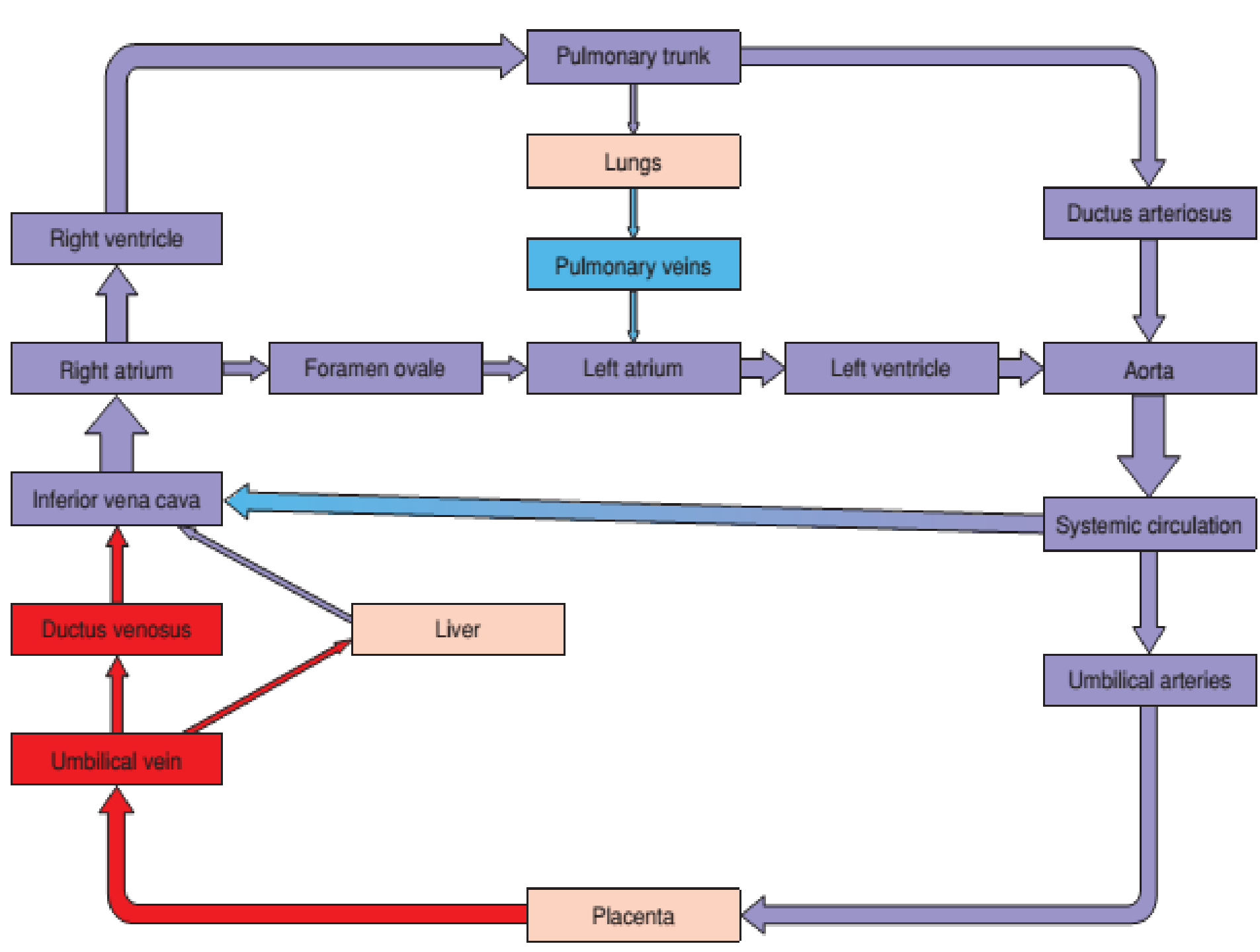
- Most of the blood in the pulmonary trunk passes through the **ductus arteriosus** into the aortic arch, where it mixes with blood coming from the left ventricle.
- Blood is returned to the placenta by the two umbilical arteries that arise from the internal iliac arteries.
- Notice that, in the fetus, oxygen-rich blood is transported by the inferior vena cava to the heart, and via the foramen ovale and ductus arteriosus to the systemic circulation.



- ◉ Important changes occur in the cardiovascular system at birth.
- ◉ The foramen ovale, ductus arteriosus, ductus venosus, and the umbilical vessels are no longer necessary.
- ◉ The foramen ovale abruptly closes with the first breath of air because the reduced pressure in the right side of the heart causes a flap to cover the opening.
- ◉ This reduction in pressure occurs because the vascular resistance to blood flow in the pulmonary circulation falls far below that of the systemic circulation when the lungs fill with air. The pressure in the inferior vena cava and right atrium falls as a result of the loss of the placental circulation.
- ◉ The constriction of the ductus arteriosus occurs gradually over a period of about 6 weeks after birth as the vascular smooth muscle fibers constrict in response to the higher oxygen concentration in the postnatal blood.
- ◉ The remaining structure of the ductus arteriosus gradually atrophies and becomes nonfunctional as a blood vessel.



16.42 Fetal circulation. (Arrows indicate the direction of blood flow.)



# HEPATIC PORTAL SYSTEM

- ◉ A vein that carries blood from one capillary network to another is called a portal vein
- ◉ The hepatic portal vein receives blood from capillaries of gastrointestinal organs and the spleen and delivers it to the sinusoids of the liver
- ◉ Hepatic portal system presents nutrient rich food, which may also be a potential source of microbes and intoxicants, to the liver for processing and clearance.

- Hepatic portal vein is formed by the union of superior mesenteric vein and splenic vein
- The superior mesenteric vein receives blood from the small intestine, parts of large intestine, pancreas and parts of stomach ( through jejunal, ileal, ileo-colic, right colic, middle colic, pancreaticoduodenal and right gastroepiploic veins)
- The splenic vein drains bloods from the stomach, pancreas and portions of large intestine through
  - i. The inferior mesenteric vein from the large intestine.
  - ii. The pancreatic vein from the pancreas, and
  - iii. The left gastroepiploic vein from the stomach.



- ◉ The hepatic portal vein then continues to the liver but before that it receives right and left gastric veins from stomach and cystic vein from gallbladder
- ◉ The processed blood then leaves the liver through right and left hepatic veins which empties into the inferior venacava before it moves up the diaphragm.
- ◉ As a result of the hepatic portal system, the absorbed products of digestion must **first pass** through the liver before entering the general circulation.

